

*Opšti pregled/
Opšti pregled*

NEUROFIBROMATOSIS: AUDIOLOGIC
AND GENETIC MANIFESTATIONS

NEUROFIBROMATOSIS: AUDIOLOŠKE
I GENETSKE MANIFESTACIJE

Correspondence to:

Ali A. Danesh, Ph.D. Associate
Professor, Director of Audiology Clinic,
Associate Professor of Biomedical
Sciences Department of Communication
Sciences and Disorders Florida Atlantic
University
777 Glades Road
P.O. Box 3091
Boca Raton, Florida 33431-0991

+1.561.297.2071 (office)

+1.561.297.2258 (Clinic)

+1.561.297.2268 (Fax)

E-mail: danesh@fau.edu

www.coe.fau.edu/csd/DrDanesh.htm

Ali A. Danesh.¹⁻² Meredith Buemi³ Connie Keintz¹

¹ Department of Communication Sciences and Disorders, Florida
Atlantic University, Boca Raton, Florida, USA 33431

² Labyrinth Audiology, Inc., Boca Raton, Florida, USA 33486

³ South Florida ENT Associates/Greater Miami Audiology, Hollywood,
FL 33031

Abstract

Ključne reči

Neurofibromatosis (NF), glavni tipovi NF,
dominantno nasledene mutacije,
hirurško lečenje

Key words

Neurofibromatosis (NF), Genetics, autosomal
dominant inheritance, Vestibular
Schwannoma, Auditory Brainstem Implant,
Audiology

Neurofibromatosis (NF) a multi-faceted genetic disorder has been known to affect many portions of peripheral and central nervous systems. There are two major types of NF which are referred to as Types 1 and 2. Although the genetic backgrounds between both types include different chromosomes, they both involve autosomal dominant inheritance of mutations on tumor suppressor genes. NF1 is a more prevalent condition and includes a variety of abnormalities such as optical involvements and skeletal, cutaneous and neurological abnormalities. The NF type 2 engages more auditory-related features and its cardinal finding is vestibular schwannoma. Treatments include surgical removal or stereotactic radio surgery followed by rehabilitation for cochlear or auditory brainstem implants.

INTRODUCTION

Initially described in 1882 by Friedrich Daniel von Recklinghausen, neurofibromatosis (NF) is also fittingly known as von Recklinghausen disease (Sobol, Rappaport, Al-Abdulhadi & Mohr, 2001). NF can be defined as an autosomal dominant genetic condition that presents with multiple tumors involving the peripheral and central nervous systems, including the auditory nerve (Huson, 2008). Historically, this disease appeared as a medical mystery; however, with the advancement of technology, neurofibromatosis has become a more recognizable disease. Neurofibromatosis was later classified into eight separate types, however, only two remain universally recognized: neurofibromatosis type 1 (NF1) and type 2 (NF2) (Boyd, Korf & Theos, 2009). While NF1 can affect as many as 1 in 3500 people, NF2 is much rarer, affecting as few as 1 in 40,000 individuals (Boyd, Korf & Theos, 2009; Baser, et al., 2002). Neurological symptoms are common and there is a high frequency of bilateral vestibular schwannomas associ-

ated with NF2 (Ferner, 2007). As an audiologist, it is important to recognize the clinical applications of this genetic disorder due to the effects it has on the auditory system. The purpose of this review paper is to describe the two types of neurofibromatosis, the various common clinical presentations of each, diagnostic criteria, as well as treatment and audiological management. The primary focus of this paper will be directed toward neurofibromatosis type 2, as it is more clinically applicable in auditory-related clinics than NF type 1.

NF TYPE 1

Neurofibromatosis type 1 affects approximately 1 in 3500 live births world-wide (Boyd, Korf & Theos, 2009). It can be described as an autosomal dominant disorder affecting multiple systems within the human body. These can include but are not limited to: cutaneous, skeletal, neurological/psychological and ophthalmological abnormalities (Boyd, Korf & Theos, 2009). Although NF1 is the more prevalent type of neurofibromatosis, its audiological represen-

tation its hearing and balance complications are more limited compared to NF2. Despite this fact, it is important to understand the difference between the two types and be able to distinguish between their common characteristics and diagnostic criteria.

Genetics

It has been discovered that NF1 results from a mutation on the long arm of chromosome 17 (17q11.2) in a tumor suppressor gene called the NF1 gene (Boyd, Korf & Theos, 2009). Half of these mutations are caused by familial inheritance and half are spontaneously acquired during embryonic development (Siqveland & Pond, 2009). According to Stocker et al. (1995) the NF1 gene is responsible for encoding the protein neurofibromin, which is expressed throughout cells of neurons, glial and Schwann cells (as cited by Boyd, Korf & Theos, 2009). Neurofibromin is an important regulator of cell proliferation, thus dysfunction of this protein can cause uncontrollable cell production and tumor growth involving neural cells (Boyd, Korf & Theos, 2009).

Common Characteristics

Due to the various mutations involved in this disorder, clinical characteristics can vary from person to person. The hallmark characteristic of NF1 is the presence of multiple café-au-lait spots, which are darkening of the skin pigmentation resembling birth marks. It is the presence of these spots in combination with multiple neural tumors that truly highlight this disorder (Suenobu, Akiyoshi, Maeda, Korematsu & Izumi, 2008). Other common characteristics involve tumors of the optic pathway, skeletal malformations and a variety of abnormal skin growths.

NF1 does not typically affect the auditory system directly. However, indirect effects to hearing can be a result of vascular, neural and psychological involvements. According to the National Institute of Health (NIH) common associated conditions are hydrocephalus, learning/cognitive impairments and vascular problems (NINDS/NIH, 2009). Due to the varied causes and effects of NF1 on the auditory system, there is not a specific hearing loss that conforms to this disorder. However, when sensorineural hearing loss is diagnosed in combination with the presence of multiple café-au-lait spots, neurofibromatosis should be considered.

Diagnosis

While there are a large number of mutations that cause this disorder, specific diagnostic criteria exists for patients with NF1. This criteria has been described and revised by multiple institutions, however, the NIH utilizes the most sensitive criteria (NINDS/NIH, 2009). The NIH describes seven characteristics, where a person must have at least two in order to be diagnosed with NF1. Their criteria includes: six or more café-au-lait spots that are larger than 5 mm (children) or 15 mm (adults), two or more neurofibromas (or one plexiform), armpit or groin freckles, two or more Lisch nodules (growths on the iris), an optic nerve tumor, abnormal development of the spine, temple bone or tibia and a blood relative diagnosed with NF1 (NINDS/NIH, 2009).

NF TYPE 2

Neurofibromatosis type 2, also known as acoustic neurofibromatosis, is a much more rare condition, affecting approximately 1 in 33-40,000 people worldwide (Baser, et al. 2002). Although clinical symptoms typically arise in early childhood, nearly 100% penetrance of the disease can be expected by age 60 (Baser, et al. 2002). Unlike type 1, neurofibromatosis type 2 has much greater direct effects on the auditory system. Neurofibromatosis type 2 will be reviewed in greater detail in this paper, as it has important clinical features in audiology.

Genetics

Although both types are called neurofibromatosis, NF1 and NF2 are caused by mutations on two separate chromosomes. Type 2 neurofibromatosis is caused by a mutation in the NF2 gene, located on the long arm of chromosome 22 (Sobol, et al. 2001). The NF2 gene encodes for a protein known as merlin, which is involved in the co-ordination of two intra-cellular processes responsible for cell growth (Vincenti, Pasanisi, Guida, Trapani, & Sanna, 2008; Huson, 2008). Similar to NF1, 50% of NF2 mutations are caused from familial inheritance and 50% from spontaneous or novel mutations (Sobol, et al. 2001). As with any autosomal dominant disorder, the risk of having affected offspring if one of the parents is affected is 50%. It is possible to complete genetic prenatal testing, although prediction of severity of impairment is uncertain (Redman, 2007).

Common Characteristics

NF2 has a much more severe involvement with the auditory system and can have a more serious associated morbidity (Huson, 2008). The hallmark clinical symptom in patients with NF2 is bilateral vestibular schwannomas that can cause hearing loss, tinnitus, facial nerve weakness and/or dizziness problems usually in early adulthood (Sobol, et al. 2001). Patients with NF2 also tend to have ophthalmic related problems during childhood, which can include cataracts and meningiomas on the optic nerve (Huson, 2008). Other characteristics of patients with NF2 typically include cutaneous, spinal and cranial nerve tumors with involvement of multiple peripheral nerves (Evans, 2009).

The vestibular schwannomas that result from NF2 are also invasive and can quickly involve many surrounding cranial nerves. Whereas sporadic schwannomas are typically extremely slow growing and tend to compress the involved nerve, NF2 schwannomas are slightly faster growing and usually multifocal, lobular and more vascular (Evans, 2009). As a result of their invasive nature, majority of patients presenting with NF2 tend to have a quickly progressive hearing loss and eventually become deaf (Sobol, 2001; Evans, 2009). Figure 1 a-b below represents serial audiologic tests of a 26 years old male with NF2. This patient showed a progressive loss of hearing in a 15 year period. As it is shown on this figure the hearing thresholds were within normal ranges in 1996 and dropped to profound to total hearing loss in the right ear and moderate to severe hearing loss in the left ear.

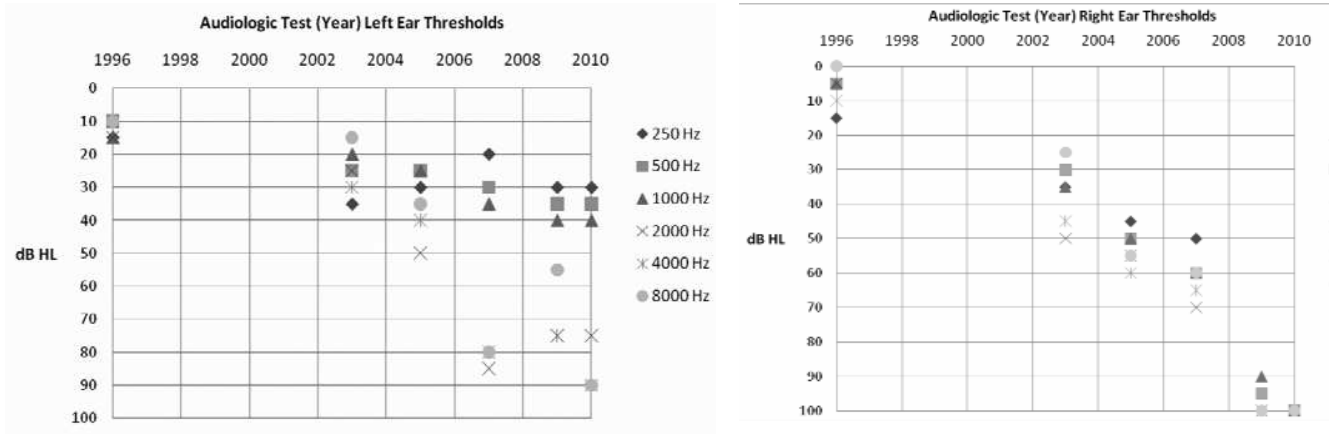


Figure 1 a-b. Representation of bilateral hearing threshold shifts from 1996 to 2010 in a patient with Neurofibromatosis Type 2 (NF2). Note that by early 2010 the patient had sloping moderate to severe hearing loss in the left ear and no profound hearing loss in the right ear.

Diagnosis

There are three major organizations that have outlined the diagnostic criteria for neurofibromatosis type 2: NIH, a group known as Manchester and the National Neurofibromatosis Foundations (NNFF) (NINDS/NIH, 2009). The criteria between each differs slightly but all include some version of bilateral vestibular schwannomas, first-degree blood relative with NF2, multiple meningiomas, ophthalmic abnormalities and unilateral vestibular schwannoma in combination with any of the previous (NINDS/NIH, 2009). Due to the invasive nature of tumors present in patients with NF2, patients with affected parents should begin screening at birth or by 10 years of age for those without family history (Evans, 2009). Diagnostic methods can include clinical and family history, examinations (dermatologic, otologic/audiologic and ophthalmic), MRI of the brain and spine, and molecular analysis (Evans, 2009).

A study by Baser et al. (2002) evaluated the sensitivity of the three organizations' diagnostic criteria. This study concluded that the Manchester criteria contained the most sensitive criteria for definitively diagnosing patients with NF2. Their criteria include specific guidelines for people with and without a positive family history of NF2 and also the inclusion of persons with a unilateral vestibular schwannoma without an age of diagnosis, as the NNFF criteria includes, which can exclude diagnosis of this disease (Baser, et al. 2002). Therefore, it is suggested that clinicians use the Manchester criteria for a more sensitive diagnosis of patients with NF2.

Treatment

As a result of the high prevalence of nerve tumors in patients with NF2, treatment methods typically focus on the tumor control, especially for patients with vestibular schwannomas. This can include close observation, surgical removal and/or radio surgery utilizing gamma knife and prognosis can vary depending on age of onset and number of tumors (Evans, 2009). Treatment methods of patients should be considered on a case-by-case basis due to the high variability of symptoms and severity among patients. The multi-system nature of NF2 also suggests the need for a highly specialized multi-disciplinary team including orthopedic surgeons, otolaryngologists and ophthalmologists (Evans, 2009).

Surgical removal of vestibular schwannomas is the preferred treatment method, although gamma knife radio surgery also has its application. Gamma knife radiation is a good option to consider in patients who may not be traditional surgical candidates such as elderly patients, larger tumor size and those who refuse surgery altogether (Mathieu, et al. 2007). Mathieu, et al. (2007) evaluated the outcomes related to tumor control and hearing preservation of vestibular schwannoma patients treated with stereotactic radio surgery. This study concluded that tumor control was achieved in 88% and hearing preservation was achieved in 42% of patients treated with radio surgery. Contrary to this, surgical removal of vestibular schwannomas typically diminishes any pre-surgical hearing. The study by Mathieu et al. (2007) suggests that although tumor control is typically higher in those treated with surgical removal, gamma knife radiation is a good option for patients to consider due to its less-invasive nature and decreased morbidity rates.

Audiological Management

Audiological management is usually a difficult aspect of treating patients with neurofibromatosis type 2, due to the invasive nature of the schwannomas and the detrimental effects they can have on the auditory nerve and adjacent cranial nerves. Due to the long-term medical care involved with NF2 patients, the need for some usable hearing is immensely important. The two primary forms of otological and audiological management following the successful preservation of the auditory nerve are cochlear implants (CI) and auditory brainstem implants (ABI). Both methods can have very different outcomes but each has a unique application in patients with this disease.

Cochlear implantation is possibly the more favorable option for hearing rehabilitation as it has been associated with better speech understanding (Vincenti, Pasanisi, Guida, Trapani & Sanna, 2008). Despite this fact, some professionals argue the possibility of hearing degradation over a long-term follow-up period. According to Neff, et al. (2007), a hearing degradation could be due to post-surgical trauma, such as scarring of the auditory nerve. In an effort to study these long-term effects, a study by Neff et al. (2007) investigated NF2 patients wearing cochlear implants. This study found that contrary to traditional beliefs, 5 out of 6 of their patients experienced no harmful long-term effects of surgery

or degradation of hearing up to seven years post-implantation. This implies that even with a translabyrinthine surgical approach, cochlear implants should be utilized whenever possible, as they provide the most speech understanding benefit (Neff, et al. 2007).

The benefits of cochlear implants have become widely accepted; however, auditory brainstem implants continue to have an important application in patients with NF2. A study conducted by Vincenti, et al. (2008) compared the hearing results of patients wearing a cochlear implant to those with an auditory brainstem implant. According to this study, 3 out of 4 patients with the CI achieved open-set sentence recognition of 55-100%. This was compared to the five ABI patients who had results ranging from 33-70% comprehension. Although these results favored the patients with a CI, the study reported improved environmental awareness and localization skills in the patients with an ABI (Vincenti, et al. 2008). This confirms the applicability for ABI in patients where cochlear nerve preservation is not achieved (Vincenti, et al. 2008).

CONCLUSION

In summary, there are multiple types of neurofibromatosis but the more common and hearing-related types remain NF1 and NF2 and it is important to distinguish between both types. While they both have major effects on the auditory system, NF2 has more direct effects since its main diagnostic criterion includes bilateral vestibular schwannomas. Although the genetic backgrounds between both types include different chromosomes, both involve autosomal dominant inheritance of mutations on tumor suppressor genes. The treatment methods for both types include surgical removal of operable tumors and/or some form of radiation therapy. Specifically, the treatment of NF2 includes the careful removal of vestibular schwannomas and audiological management can include either a cochlear implant or auditory brainstem implant. The results of patients with a CI are typically more favorable for speech understanding; however, in cases where the cochlear nerve is not adequately preserved, an ABI can help to restore sound awareness and localization. Cases of neurofibromatosis should be carefully managed by specialized interdisciplinary teams and are encouraged to be controlled on a case-by-case basis. As an audiologist, it is important to recognize the delicate nature of these patients and work to rehabilitate hearing in the best way possible.

Apstrakt

Neurofibromatosis (NF), multifasetirano genetsko oboljenje, poznato je po ostećenju mnogih delova perifernog i centralnog nervnog sistema. Postoje dva tipa NF, označena kao Tip1 i Tip2. Iako genetska osnova ova dva tipa uključuje različite hromosome, oba poremećaja su odraz dominantno nasleđenih mutacija tumor-suprimirajućih (supresivnih) gena. NF1 je prevalentnija varijanta i uključuje spektar abnormalnosti kao što su optičke, skeletne, kožne i neurološke manifestacije. Tip NF2 je karakterističan više po auditornim poremećajima sa kardinalnim nalazom u vidu vestibularnog švanoma. Tretman uključuje hirurško uklanjanje ili stereotaktičku radiohirurgiju praćenu rehabilitacijom za kohlearni implant ili implant u auditornom području moždanog stabla.

REFERENCES

- Baser, M., Friedman, J., Wallace, A., Ramsden, R., Joe, H., & Evans, D. (2002). Evaluation of clinical diagnostic criteria for neurofibromatosis 2. *Neurology*, 59; 1759-1765.
- Boyd, K., Korf, B., & Theos, A. (2009). Neurofibromatosis type 1. *American Academy of Dermatology*, 61(1).
- Evans, G (2009). Neurofibromatosis type 2 (NF2): A clinical and molecular review. *Orphanet Journal of Rare Diseases*, 4(16).
- Ferner, R.E. (2007). Neurofibromatosis 1 and neurofibromatosis 2: A twenty first century perspective. *Lancet Neurology*, 6: 340-351.
- Huson, S. (2008). Neurofibromatosis: Emerging phenotypes, mechanisms and management. *Clinical Medicine*, 8(6); 611-617.
- Mathieu, D., Kondziolka, D., Flickinger, J., Niranjana, A., Williamson, R., Martin, J., et al. (2007). Stereotactic radiosurgery for vestibular schwannomas in patients with neurofibromatosis type 2: An analysis of tumor control, complications and hearing preservation rates. *Neurosurgery*, 60(3); 460-470.
- Neff, B., Wiet, M., Lasak, J., Cohen, N., Pillsbury, H., Ramsden, R., et al. (2007). Cochlear implantation in neurofibromatosis type 2 patient: Long-term follow-up. *Laryngoscope*, 117; 1069-1072.
- NINDS Neurofibromatosis Information Page. (2009, June 3). Retrieved June 21, 2009, from National Institute for Neurological Disorders and Stroke (NINDS)/National Institute of Health (NIH): <http://www.ninds.nih.gov/disorders/neurofibromatosis/neurofibromatosis.htm>
- Redman, C. (2007). Neurofibromatosis: A guide to care in the community. *The Journal of Family Health Care*, 17, 95-97.
- Siqveland, E. & Pond, D. (2009). Neurofibromatosis type 1: Update of a common genetic condition. *Minnesota Medicine*, 92(3); 49-52.
- Sobol, S., Rappaport, J., Al-Abdulhadi, K. & Mohr, G. (2001). Diagnosis of neurofibromatosis type 2 in a patient with long-standing bilateral sensorineural hearing loss. *The Journal of Otolaryngology*, 30(6); 368-371.
- Suenobu, S., Akiyoshi, K., Maeda, T., Korematsu, S., & Izumi, T. (2008). Clinical presentations of patients with neurofibromatosis type 1 in infants and childhood: Genetic traits and gender effects. *Journal of Child Neurology*, 23(11); 1282-1287.
- Vincenti, V., Pasanisi, E., Guida, M., Trapani, G., & Sanna, M. (2008). Hearing rehabilitation in neurofibromatosis type 2 patients: Cochlear versus auditory brainstem implant. *Audiology & Neurotology*, 13; 273-380.