

*Prikaz bolesti/
Case reports*

SPLENOSIS AS A DIAGNOSTIC DILEMMA –
A case report

SPLENOZA KAO DIJAGNOSTIČKA DILEMA
– *Prikaz slučaja*

Correspondence to:

Nataša Rakonjac, dr
Clinical Hospital Centre Zemun,
Belgrade, Vukova 9
Tel. 011/ 377-26-29, 011/ 319-22-04
Mob. 064/ 195-03-50
E mail: natasarakonjac@yahoo.com

**Nataša Rakonjac, Vladimir Čotrić, Aleksandar Mandarić,
Aleksandar Stanojević**

Clinical Hospital Centre Zemun, Belgrade

Key words

splenosis, splenic injury, splenic-like masses, peritoneal nodule

Ključne reči

splenoza, trauma slezine, mase nalik slezini, peritonealni nodusi

Abstract

Splenosis is a benign condition caused by autotransplantation of splenic tissues after splenic trauma or surgery. It is usually diagnosed accidentally. However, occasionally splenosis is a significant diagnostic dilemma, especially when this condition is presents as a significant large lymphatic nodules or metastatic malignant disease on abdominal imaging. This is the case report of a 41-year-old man, who underwent post-traumatic splenectomy following blunt trauma 10 years ago. The patient complaining of low back pain, at the same time laboratory tests were normal. Abdominal ultrasound revealed no spleen and enlarged lymph nodes in the left hemiabdomen. In addition, the CT scan shows rounded nodules, which have expected density of the spleen. The diagnosis was confirmed with Technetium-99m (Tc-99m) sulfur colloid scintigraphy. Splenosis should be considered when a differential diagnosis of tumor-like lesions disclosed on abdominal imaging occurs in a patient with a splenic injury in the past.

INTRODUCTION

Splenosis is a benign, usually asymptomatic, condition involving autotransplantation of splenic tissue that occurs frequently after splenic rupture caused by trauma or surgery (1). The interval of time between the initial trauma and the diagnosis varies from 3 to 45 years with an average interval of 21 years (2). The blood supply in splenosis however, is derived from the surrounding tissues and vessels, without any association to the splenic artery (3). The tissue in splenosis usually reveals distorted architecture with no hilum, a poorly formed capsule and tissue of any shape or size (4). Splenosis is usually found incidentally and unless symptomatic, therapy is not indicated. However, due to the rarity of this condition and the concern for malignancy with the growth of the nodules over time, a tissue diagnosis is usually pursued-most often intraoperatively (5). Our case was diagnosed using non-surgical modalities.

CASE REPORT

A 41 year old male was referred to the out-patient urology department with complaints of occasional low back pain. He had undergone post-traumatic splenectomy and blood transfusions after a blunt injury about 10 years ago. The physical examination was remarkable only for the presence of a postoperative abdominal scar. Initial routine laboratory

tests including complete blood count, urology laboratory tests, gamma-glutamyl transferase, alkaline phosphatase, aminotransferases, amylase, glucose, electrolytes and blood lipids did not reveal any abnormalities. He denied any symptoms suggestive of adrenal hormone hypersecretion, and the physical examination was negative for any signs of hyperfunctioning adrenal tumor. Esophagogastroduodenoscopy showed mild gastritis. Abdominal ultrasound revealed no spleen, and a few enlarged lymph nodes in the left hemiabdomen (Figure 1).

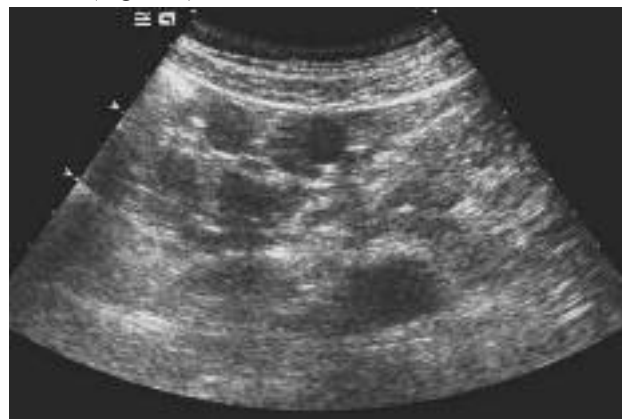

Figure 1. Ultrasound reveals multiple round nodules around the left kidney

CT scan disclosed numerous oval soft-tissue peritoneal nodules located in the left paracolic space which showed slight hypodensity during the pre-contrast phase, inhomogeneous contrast-enhancement during the arterial phase and slightly iso-hypodensity during the portal phase and have expected density of the spleen. The spleen was not visualized on the CT scan and splenosis was suspected as a possible diagnosis and a second-look ultrasound (US) exam confirmed the presence of peritoneal solid splenic-like masses on the sites indicated by CT (Figure 2).

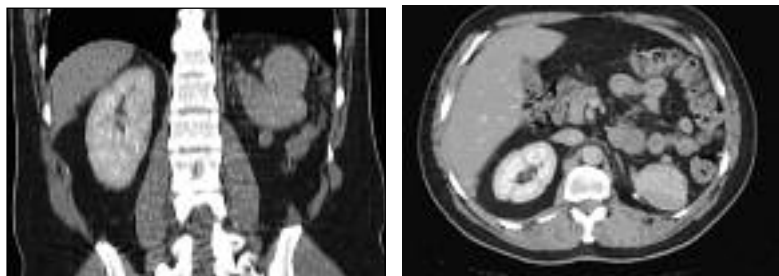


Figure 2. CT reveals multiple round nodules in left paracolic space

Additional examinations including tumor markers, chest radiography, colonoscopy and neck ultrasound were negative. Patient underwent to Tc-99m sulfur colloid scintigraphy which showed multiple oval splenic implants in the abdomen. Some of them adjacent to the diaphragm (Figure 3). Subsequently, abdominal splenosis following the post-traumatic splenectomy was diagnosed.

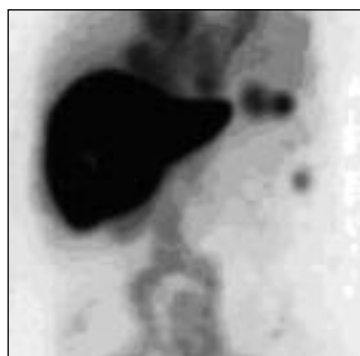

Figure 3. Tc-99m sulfur colloid scintigraphy

DISCUSSION

The first report of a splenosis case dates back to 1896, was described by Albrecht in Germany (6). Splenosis usually occurs in the left upper quadrant of the abdomen (7), however, other intraabdominal locations have been also described (8-10). Splenic autotransplants are also found in the thoracic cavity, subcutaneously or even intracranially (11,12). The incidence of abdominal splenosis in the general population remains unknown. According to Muller and Ruthlin, who performed ultrasonographic follow-up studies in patients after post-traumatic splenectomy, presumed abdominal splenosis (without histological confirmation) occurred in one-third of patients (13). Splenosis, usually results from trauma, is mostly asymptomatic and splenic implants are found accidentally during unrelated diagnostic imaging or surgery. Occasionally, abdominal splenosis can cause gas-

trointestinal bleeding (14) or abdominal pain due to bowel obstruction, intraperitoneal nodule infarction, hematoma, enlarging abdominal or pelvic masses, ureteral obstructions and hydronephrosis (15,16).

Abdominal ultrasound and radiological studies show limited diagnostic value in abdominal splenosis (17). Sonographic findings are not specific and reveal round and oval soft-tissue masses in the various locations. Low density of splenic tissue makes it difficult to visualize on standard X-rays. CT reveals the number, shape, size and location of nodules. On unenhanced and contrast-enhanced CT, the masses are similar in attenuation to the expected appearance of otherwise normal splenic tissue. On MRI, the intensity and enhancement of the splenic nodules resemble that of normal splenic tissue (18). This imaging reveals locations and characteristics, but not identity of the nodules. Sonographic and radiological picture of abdominal splenosis may be confused with numerous conditions such as metastatic disease, abdominal lymphoma, carcinomatosis, hemangiomas, peritoneal mesothelioma, multifocal endometriosis, primary renal or hepatic malignancy, accessory spleens (19). Splenosis occurring in close proximity to the adrenal glands is rare but may mimic an adrenal tumor, especially when inseparable from the adrenal by imaging or coincident with symptoms, such as uncontrolled hypertension, which might resemble hormone hypersecretion (20).

At present, noninvasive Tc-99m sulfur colloid scanning is the mainstay in the diagnosis of splenosis. The mechanism is very simple - Tc-99m sulphur colloid is sequestered in the reticuloendothelial system and detects heterotopic splenic tissue (21-23).

If the diagnosis is confirmed preoperatively by appropriate imaging and radionuclide modalities in a patient with history of abdominal trauma, laparotomy can be avoided.

Therefore, the current opinion is that when splenosis is diagnosed, surgical removal is recommended only in the case of symptomatic/complicated splenosis and in patients with hematological disease for whom splenectomy is beneficial (24). Surgical approach should be also indicated in the case of an uncertain diagnosis, especially when scintigraphic methods are not readily available and there is a suspicion of a malignant disease (25).

CONCLUSION

Abdominal splenosis remains a rare finding in clinical practice. In most reported cases in the literature, the diagnosis was not considered before surgery. This approach may obviate the need for invasive evaluation for a primary or secondary neoplasm, and thus unnecessary surgery, and therefore preserve probable functional splenic tissue. Our case was diagnosed using non-surgical modalities.

Sažetak

Splenoza je benigno stanje izazvano autotransplantacijom slezinskog tkiva posle traume ili operacije. Obično se dijagnostikuje slučajno. Međutim, splenoza je značajna dijagnostička dilema, posebno kada se, prilikom snimanja abdomena različitim metodama medicinskog slikanja, prikazuje kao signifikantno uvećani limfni nodusi ili metastatsko maligno oboljenje. Prezentujemo slučaj muškarca starog 41 godinu, koji je 10 godina ranije, posle udara tupim predmetom, podvrgnut posttraumatskoj operaciji slezine. Osim prisutne simptomatologije lumbalnog bola, ostali nalazi bili su uredni. Ultrazvuk abdomena pokazao je nepostojanje slezine, ali i uvećane limfne noduse u levom hemiabdomenu. Pored toga, CT je prikazao kružne noduse istih denziteta kao moguće tkivo slezine. Dijagnoza je potvrđena Tc-99m sulfid koloid scintigrafijom. Splenoza treba razmotriti kao diferencijalnu dijagnozu kod tumorskih lezija koje se javljaju kod pacijenta sa traumom slezine u istoriji bolesti.

REFERENCES

1. Fremont RD, Rice TW. Splenosis: a review. *South Med J.* 2007; 100:589–93.
2. Yammine JN, Tatim A, Barari A. Radionuclide imaging in the thoracic splenosis and a review of the literature. *Clin Nucl Med.* 2003; 28:121–3.
3. Case Records of the Massachusetts General Hospital, Weekly Clinicopathological Exercises: Case 29, *N Engl J Med.* 1995; 333: 784-91.
4. Tingmin L, Chunfeng M. Silent pelvic splenosis: Case report. *Int J Surg Case Rep.* 2015; 13:129–30.
5. Bizekis CS, Pua B, Glassman LR. Thoracic splenosis: mimicry of a neurogenic tumor. *J Thorac Cardiovasc Surg.* 2003; 125:1155–6.
6. Albrecht H. Ein Fall von Zahlreichen, uberganze Peritoneum versprungtent Nebenmilzer. *Beitr Path Anat.* 1896; 20:513.
7. Książczyńska D. A case report of Abdominal Splenosis – a Practical MiniReview for a Gastroenterologist. *J Gastrointestin Liver Dis.* 2011; 20:321-4.
8. Di Costanzo GG, Picciotto FP, Marsilia GM, Ascione A. Hepatic splenosis misinterpreted as hepatocellular carcinoma in cirrhotic patients referred for liver transplantation: report of two cases. *Liver Transpl.* 2004; 10:706-9.
9. Abu Hilal M, Harb A, Zeidan B, Steadman B, Primrose JN, Pearce NW. Hepatic splenosis mimicking HCC in a patient with hepatitis C liver cirrhosis and mildly raised alpha feto protein; the important role of explorative laparoscopy. *World J Surg Oncology.* 2009; 7:1.
10. Fiamingo P, Veroux M, Da Rold, et al. A rare diagnosis for a pancreatic mass: splenosis. *J Gastrointest Surg.* 2004; 8:915-6.
11. Cohen E.A. Splenosis: review and report of subcutaneous splenic implant. *A.M.A. Archives of Surgery.* 1954; 6:777–84.
12. Rickert CH, Maasjosthusmann U, Probst-Cousin S, August C, Gullotta F. A unique case of cerebral spleen. *Am J SurgPathol.* 1998; 22:894-6.
13. Muller U, Rothlin M. Milzne ubil dun-gennach traumatisch bedingter splenektomie-diagnostik und function. *Swiss Surg.* 1995; 5:230-5.
14. Basile RM, Morales JM, Zupanec R. Splenosis: a cause of massive gastrointestinal hemorrhage. *Arch Surg.* 1989; 124:1087-9.
15. Sikov WM, Schiffman FJ, Weaver M, Dyckman J, Schulman R, Torgan J. Splenosis presenting as occult gastrointestinal bleeding. *Am J Hematol.* 2000; 65:56-61.
16. Varma DG, Campeau RJ, Kartchner ZA, Karnik S. Scintigraphic detection of splenosis causing ureteral compression and hydronephrosis. *Am J Roentgenol.* 1991; 156:406.
17. Delamare J, Capron JP, Drouard F, Joly JP, Deschepper B, Carton S. Splenosis: ultrasound and CT findings in a case complicated by an intraperitoneal implant traumatic hematoma. *Gastrointest Radiol.* 1988; 13:275-8.
18. Tsitouridis I, Michaelides M, Sotiriadis C, Arvaniti M. CT and MRI of intraperitoneal splenosis. *Diagn Interv Radiol.* 2010; 16:145–9.
19. Zitzer P, Pansky M, Maymon R, Langer R, Bukovsky I, Golan A. Pelvic splenosis mimicking endometriosis, causing low abdominal mass and pain. *Hum Reprod.* 1998; 13:1683–5.
20. Pablo V, Jamie C, Lynn M, Bryan MI, Howard L. Splenosis: an uncommon cause of right „adrenal incidentaloma“ case report and review of the literature. *Clinical Case Rep.* 2015; 1:100-4.
21. Armas RR. Clinical studies with spleen-specific radiolabeled agents. *Semin Nucl Med.* 1985; 15:260-75.
22. Gunes I, Yilmazlar T, Sarikaya T, Akbunar T, Irgil C. Scintigraphic detection of splenosis: superiority of tomographic selective spleen scintigraphy. *Clin Radiol.* 1994; 49:115-7.
23. Atkins HL, Goldman AG, Fairchild RG, et al. Splenic sequestration of Tc-99m labeled, heat treated red blood cells. *Radiology.* 1980; 136:501-3.
24. Buchbinder JH, Lipkoff CJ. Splenosis: multiple peritoneal splenic implants following abdominal injury. *Surgery.* 1939; 6:927.
25. Barbaros U, Dincag A, Kabul E. Minimally invasive surgery in the treatment of splenosis. *Surg Laparosc Endosc Percutan Tech.* 2006; 16:187-9.