

*Opšti pregledi/  
General reviews*

ECHOCARDIOGRAPHY AND SUDDEN  
CARDIAC DEATH IN ATHLETES

ECHOKARDIOGRAFIJA I IZNENADNA  
SRČANA SMRT SPORTISTA

**Correspondence to:**

**Marija Zdravkovic**, MD, PhD,  
Research Fellow  
University Hospital Medical Center  
Bezanijska kosa  
Belgrade School of Medicine, University  
of Belgrade  
Autoput bb  
11000 Belgrade, Serbia  
Phone: +381113010707

E-Mail: majadare@eunet.rs

**Marija Zdravkovic**<sup>1,3</sup>, **Mirjana Krotin**<sup>1,3</sup>,  
**Bosiljka Vujisic-Tesic**<sup>2,3</sup>, **Ivana Nedeljko**<sup>2,3</sup>,  
**Jovan Perunicic**<sup>2,3</sup>, **Sanja Mazic**<sup>3,4</sup>

<sup>1</sup>University Hospital Medical Center Bezanijska kosa, Belgrade, Serbia

<sup>2</sup>Clinical Center of Serbia, Belgrade, Serbia

<sup>3</sup>Faculty of Medicine, University of Belgrade, Serbia

<sup>4</sup>Institute for Physiology, Faculty of Medicine, Belgrade, Serbia

**Key words**

echocardiography, sudden cardiac death, diagnosis, athletes, prognosis, diastolic function, systolic function, left atrium, aortic root, Doppler tissue imaging

**Ključne reči**

ehokardiografija, iznenadna srčana smrt, dijagnoza, sportisti, prognoza, dijastolna funkcija, sistolna funkcija, leva pretkomora, koren aorte, tkivni dopler

**Abstract**

Although there is no doubt that physical exercise and competitive sport are healthy, improving quality of life and life expectancy, a number of tragic sudden deaths involving young competitive athletes were reported in the press in recent years. Underlying cardiac disorders are the most common cause of sudden death during sports activities. Left ventricular remodeling is associated with a long-term athletic training. Echocardiography is an easy, non-invasive and efficient way to the precise distinction between these exercise-induced changes, called "physiological" hypertrophy, that revert after detraining, and those of cardiac disorders or "pathological" hypertrophy. The identification of a cardiac disease in an athlete usually leads to his disqualification in an attempt to reduce the risk. On the other hand, a false diagnosis of a cardiac disease in an athlete may also lead to disqualification, thus depriving him of the various benefits from sports participation. Pronounced left ventricular dilatation and hypertrophy should always be suspected for underlying cardiac disease. Physiological left ventricular remodeling is associated with normal systolic and diastolic left ventricle function. Both global and regional left ventricle diastolic function should be evaluated. New echocardiographic techniques ( tissue Doppler imaging, strain rate) have revealed "super - diastolic" left ventricle function in athletes, adding the new quality in differential diagnosis of athlete's heart syndrome.

**INTRODUCTION**

Although there is no doubt that physical exercise and competitive sport are healthy, improving quality of life and life expectancy, a number of tragic sudden deaths involving young competitive athletes were reported in the press in recent years (1). Sudden death among athletes is very rare (1:50,000–1:100,000 annually) but it is still 2–4 times more frequent than in the age-matched control population and attracts significant media attention. (2, 3). The risk-benefit ratio varies according to the athlete's age, physical capacity, and state of health (4); nevertheless, underlying cardiac disorders are the most common cause of sudden death during sports activities (5,6).

Although athletes are considered to be the healthiest part of the population, it has been found that adolescent and young athletes have a 2.8-fold greater risk of sudden cardio-

vascular death (SCD) than their sedentary counterparts (7,8). The incidence of sudden cardiac death in young people (age <35 years) is estimated to be 2.1 cases per 100,000 athletes per year from cardiovascular causes and 2.3 per 100,000 from all causes in Europe (7), while in the USA the corresponding rate is 0.96 per 100,000 athletes per year (9).

**Preparticipation screening – current recommendations**

Regular pre-participation cardiovascular screening is the best way to the identification of athletes affected by cardiovascular diseases (10,11). The American Heart Association as well as the European Society of Cardiology have published guidelines for the cardiovascular screening of athletes, aiming to detect the high-risk athletes and to prevent undesirable events (11,12). However, according to these recommenda-

tions, echocardiographic examination is not in the first line of diagnostic and it should be recommended in selected athletes, after standard medical examination (13). The results of several studies based on the cost-effectiveness ratio of the proposed guidelines for pre-participation cardiovascular screening raised some doubts about the additional use of echocardiography (14,15). Around 30% of sudden death cases cannot be precluded by current proposed medical screening of athletes, even when an ECG examination is included (16). Transthoracic echocardiography significantly improves the diagnostic power of screening in the detection of both mild and serious cardiac conditions in the athletic population. In the recently published study Rizzo et al. have shown that additional echocardiographic examination in apparently healthy boys referred for pre-participation screening revealed in almost 1.8 % of the athletes a structural cardiac lesion with potential future complication (17).

### Left ventricle remodeling

A long-term athletic training in adult athletes is associated with changes in cardiac morphology, including increased left ventricular (LV) cavity dimension, wall thickness and mass. These changes have been extensively studied and are commonly described as “athlete’s heart”, a positive adaptation to exercise suiting an athlete very well (18-20).

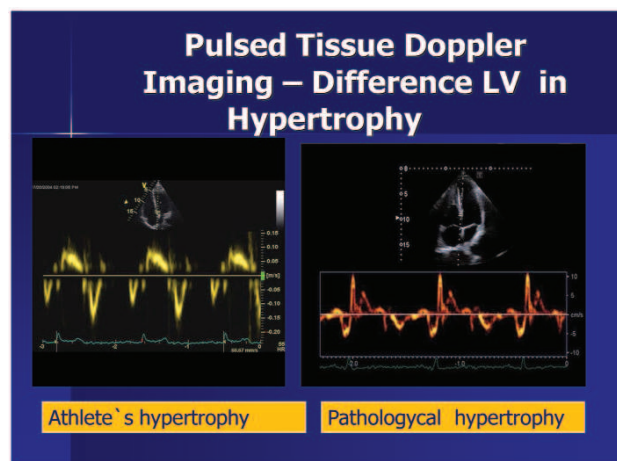
The “athlete’s heart” syndrome was described by Henschen in 1899, using only a basic physical examination with a careful percussion for the recognition of the enlargement of the heart caused by the athletic activity in cross-country skiers (21). Henschen (21) concluded that both dilatation and hypertrophy were present, involving both the left and right sides of the heart, and that these changes were normal and favourable.

The extent of changes in cardiac morphology varies between sports and previous training duration and may complicate the differentiation between normal physiologic changes and hypertrophic and dilatative cardiomyopathy, recognised as causes of a sudden death in young athletic population (22, 23). Long-term cardiovascular adaptation leads to the left ventricle remodeling. It has been noted that adult elite professional footballers, undertaking both isotonic and isometric forms of exercise, have increased wall thickness, chamber dimensions, aortic root size, and left ventricular mass compared with healthy non-athletes (23-25). This is the consequence of the physiological action caused by two physiological laws: the law of Frank-Starling (left ventricle dilatation) and the Laplace’s law (left ventricle hypertrophy). Increase in left ventricle mass is the final product of this action.

However, the responses of individual athletes to systematic conditioning are heterogeneous. The pattern and magnitude of physiologically increased LV mass may vary with respect to the nature of sports training, but also to the athlete’s age (23, 26). There are numerous studies suggesting that specific morphological adaptations and changes in LV mass are induced by systematic training in different sports disciplines (27-31). The most extreme increases in LV wall thickness have been observed in those elite athletes training in rowing, and cycling, whereas limited data available in those athletes participating in ultra-endurance sports (such

as triathlon) paradoxically show more modest alterations in cardiac dimensions (32). Some misunderstanding persisted considering whether strength training (eg. wrestling, weight lifting) alone results in LV hypertrophy. These sports are associated with only mild increase in wall thicknesses (although often disproportionate to cavity size), whereas absolute values uncorrected for body surface area usually remain well within the accepted normal range. These differences in left ventricle remodeling, known as the “Morganroth hypothesis”, initially proposed some 30 years ago, initiated substantial and important research in the field of cardiac adaptation to physical exercise in athletes (33). However, there are some scientific debates about insufficient evidences to endorse the “Morganroth hypothesis” of differential adaptation to aerobic and resistance training (34).

Normalization of cardiac dimensions according to body size is of the highest importance in comparisons between athletes and non-athletes, as it is known that cardiac dimensions vary with body size and composition and in everyday practice is hard to use BSA-matched population (26,35-37). Cardiac dimensional alterations associated with athletic training have been defined over the past 30 years in a number of cross-sectional echocardiographic studies. However, pronounced left ventricular dilatation and hypertrophy should always be suspected for underlying cardiac disease. Physiological left ventricular remodeling is associated with normal systolic and diastolic left ventricle function (26, 38). Both global and regional left ventricle diastolic function should be evaluated (38,39). New echocardiographic techniques (tissue Doppler imaging) have revealed “super – diastolic” left ventricle function in athletes, adding the new quality in differential diagnosis of athlete’s heart syndrome (39,40). The difference in pathologic and physiologic Doppler tissue imaging patterns are shown at the Picture No 1.



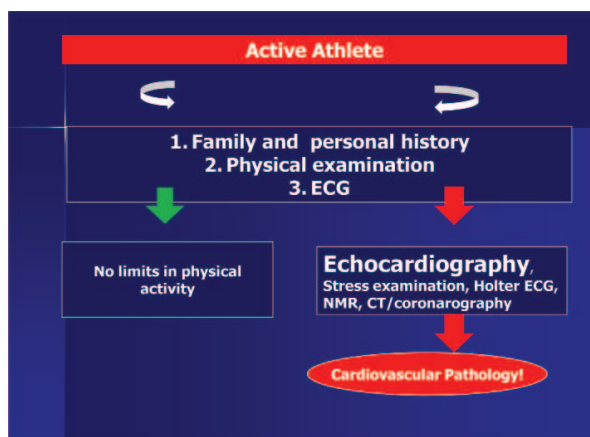
Picture No 1: The difference in pathologic and physiologic Doppler tissue imaging patterns

On the other hand, 3-dimensional echocardiographic morphologic and functional assessment of the left ventricle in Olympic athletes demonstrated a balanced adaptation of LV volume and mass, with preserved, not improved, systolic function, regardless of specific disciplines participated. Caselli (41, 42) in recently published studies have shown some improvement in athlete’s left ventricle function, that can be detected by significant shortening of the systolic time in association with a significant increase in LV emptying

velocity. These patterns of left ventricle systolic and diastolic function characterize the physiological LV adaptation of the athletes and may potentially be useful in differential diagnosis of the 'athlete heart'.

Left ventricular remodeling is also linked to the left atrial remodeling, as well as the remodeling of the aortic root (26, 43-45). A few new studies revealed that right ventricular dimensions are also affected by left ventricular remodeling, claiming the anatomical and functional unity of the two heart chambers (46-48).

The current recommendations for preparticipation athlete's screening and the role of echocardiography are displayed at the Graph No 1.



### Final remarks

Left ventricular remodeling is associated with a long-term athletic training. Echocardiography is an easy, non-invasive and efficient way to the precise distinction between these exercise-induced changes, called “physiological” hypertrophy, that revert after detraining, and those of cardiac disorders or “pathological” hypertrophy. The identification of a cardiac disease in an athlete usually leads to his disqualification in an attempt to reduce the risk. On the other hand, a false diagnosis of a cardiac disease in an athlete may also lead to disqualification, thus depriving him of the various benefits from sports participation. The correct echocardiographic quantification of the left ventricle function is of the highest importance for the athlete's health and career.

Graph No 1: The current recommendations for preparticipation athlete's screening and the role of echocardiography

### Apstrakt

Iznenadna srčana smrt je, nažalost, relativno česta kod aktivnih sportista. Veliki broj oboljenja koja su uzrok iznenadne srčane smrti mogu lako biti dijagnostikovana pretdakmičarskim ehokardiografskim pregledom. Za sada i po evropskim i po američkim preporukama za pretdakmičarsko praćenje sportista ehokardiografski pregled nije obavezan, već je indikovao u strogo selektivnim slučajevima. Ostaje pitanje adekvatne diferencijalne dijagnostike ehokardiografskih promena nastalih u sklopu fiziološkog remodelovanja srčanih struktura i početnih ehokardiografskih manifestacija patoloških stanja, potencijalnosmrtonosnih. Fiziološko remodelovanje leve komore kod sportista je uvek povezano sa očuvanom sistolnom i dijastolnom funkcijom leve komore, što nije slučaj kod patoloških stanja. Najčešći uzrok iznenadne srčane smrti kod sportista mlađjih od 35 godina u Italiji je aritmogena displazija leve komore, a u Americi, s druge strane, hipertrofična kardiomiopatija. Oba oboljenja se vrlo lako i brzo mogu dijagnostikovati ehokardiografskim pregledom. Nove ehokardiografske tehnike ( pulsni tkivni dopler, strain metoda) su pokazale da kod sportista postoji “super-dijastolna funkcija” leve komore, što je vrlo koristan parameter u diferencijalnoj dijagnozi fizioloških manifestacija “sportskog srca” i oboljenja srčanog mišića sa druge strane.

### REFERENCES

- Pigozzi F, Rizzo M. Sudden death in competitive athletes. Clin Sports. 2008; 27:153-181 .
- Corrado D, Drezner J, Basso C, Pelliccia A, Thiene G. Strategies for the prevention of sudden cardiac death during sports. Eur J Cardiovasc Prev Rehabil. 2011; 18: 197-208
- Albert CM, Mittleman MA, Chae CU, Lee IM, Hennekens CH, Manson JE. Triggering of sudden death from cardiac causes by vigorous exertion. N Engl J Med. 2000; 343: 1355-1361
- Maron BJ. The paradox of exercise. N Engl J Med. 2000; 343: 1409-1411
- Corrado D, Basso C, Thiene G. Essay: Sudden death in young athletes. Lancet. 2005; 366: S47-S48
- Westrol MS, Kapitanyan R, Marques-Baptista A, Merlin MA. Causes of sudden cardiac arrest in young athletes. Postgrad Med.2010; 122: 144-157
- Corrado D, Basso C, Rizzoli G, Schiavon M, Thiene G. Does sports activity enhance the risk of sudden death in adolescents and young adults? J Am Coll Cardiol: 2003; 42: 1959-1963
- Huston TP, Puffer JC, Rodney WM. The athletic heart syndrome. N Engl J Med. 1985; 313: 24-32
- Maron BJ, Haas TS, Doerer JJ, Thompson PD, Hodges JS. Comparison of U.S. and Italian experiences with sudden cardiac deaths in young competitive athletes and implications for preparticipation screening strategies. Am J Cardiol.2009; 104: 276-280
- Mick TM, Dimeff RJ. What kind of physical examination does a young athlete need before participating in sports? Cleve Clin J Med. 2001; 71: 587-597
- Corrado D, Pelliccia A, Bjørnstad HH, Vanhees L, Biffi A, Borjesson M, et al. Cardiovascular pre-participation screening of young competitive athletes for prevention of sudden death: proposal for a common European protocol. Consensus Statement of the Study Group of Sport Cardiology of the Working Group of Cardiac Rehabilitation and Exercise Physiology and the Working Group of Myocardial and Pericardial Diseases of the European Society of Cardiology. Eur Heart J. 2005; 26: 516-524
- Corrado D, Pelliccia A, Heidbuchel H, Sharma S, Link M, Basso C, et al; Section of Sports Cardiology, European Association of



- Cardiovascular Prevention and Rehabilitation; Working Group of Myocardial and Pericardial Disease, European Society of Cardiology. Recommendations for interpretation of 12-lead electrocardiogram in the athlete. *Eur Heart J*. 2010; 31: 243-259
13. Ljungqvist A, Jenoure PJ, Engebretsen L, Alonso JM, Bahr R, Clough AF, et al. The International Olympic Committee (IOC) consensus statement on periodic health evaluation of elite athletes, March 2009. *Clin J Sport Med*. 2009; 19: 347-365
14. Fuller CM. Cost effectiveness analysis of screening of high school athletes for risk of sudden cardiac death. *Med Sci Sports Exerc*. 2000; 32: 887-890
15. Epstein SE, Maron BJ. Sudden death and the competitive athlete: perspectives on preparticipation screening studies. *J Am Coll Cardiol*. 1986; 7: 220-230
16. Maron BJ, Doerer JJ, Haas TS, Tierney DM, Mueller FO. Sudden deaths in young competitive athletes: analysis of 1866 deaths in the United States, 1980-2006. *Circulation*. 2009; 119: 1085-1092
17. Rizzo M, Spataro A, Cecchetelli C, Quaranta F, Livrieri S, Sperandii F, et al. Structural cardiac disease diagnosed by echocardiography in asymptomatic young male soccer players: implications for pre-participation screening. *Br J Sports Med*. 2011 (Epub ahead of print)
18. Pelliccia A, Maron BJ, Spataro A, Proschan MA, Spirito P. The upper limit of physiologic cardiac hypertrophy in highly trained elite athletes. *N Engl J Med*. 1991; 324: 295-301
19. Fagard R, Aubert A, Lysens R, Staessen J, Vanhees L, Amery A. Noninvasive assessment of seasonal variation in cardiac structure and function in cyclists. *Circulation*. 1983; 67: 896-901
20. Roeske WR, O'Rourke RA, Klein A, Leopold G, Karlner JS. Non-invasive evaluation of ventricular hypertrophy in professional athletes. *Circulation*. 1976; 53: 286-292
21. Henschen S. Skilanglauf und skiwettlauf: Eine medizinische Sportstudie. *Mitt Med Klin Upsala (Jena)*. 1899; 2: 15-18
22. Spirito P, Pelliccia A, Proschan MA, Granata M, Spataro A, Bellone P. Morphology of the "athlete's heart" assessed by echocardiography in 947 elite athletes representing 27 sports. *Am J Cardiol*. 1974; 74: 802-806
23. Maron BJ. Structural features of the athlete heart as defined by echocardiography. *J Am Coll Cardiol*. 1986; 7: 190-203
24. Pelliccia A, Culasso F, Di Paolo FM, Maron BJ. Physiologic left ventricular cavity dilatation in elite athletes. *Ann Intern Med*. 1999; 130: 23-31
25. Pelliccia A, Maron BJ, De Luca R, Di Paolo FM, Spataro A, Culasso F. Remodeling of left ventricular hypertrophy in elite athletes after long-term deconditioning. *Circulation*. 2002; 105: 944-949
26. Zdravkovic M, Perunicic J, Krotin M, Ristic M, Vukomanovic V, Soldatovic I, Zdravkovic D. Echocardiographic study of early left ventricular remodeling in highly trained preadolescent footballers. *J Sci Med Sport*. 2010; 13: 602-606
27. Fagard R. Athlete's heart. *Heart*. 2003; 89: 1455-1461
28. Longhurst JC, Kelly AR, Gonyea WJ, Mitchell JH. Echocardiographic left ventricular masses in distance runners and weight lifters. *J Appl Physiol*. 1980; 48: 154-162
29. Pelliccia A, Spataro A, Caselli G, Maron BJ. Absence of left ventricular wall thickening in athletes participating in intense power training. *Am J Cardiol*. 1993; 72: 1048-1054
30. Hauser A, Dressendorfer RH, Vos M, Hashimoto T, Gordon S, Timmis GC. Symmetric cardiac enlargement in highly trained endurance athletes: a two-dimensional echocardiographic study. *Am Heart J*. 1985; 109: 1038-1044
31. Calderón FJ, Díaz V, Peinado AB, Benito PJ, Maffulli N. Cardiac dimensions over 5 years in highly trained long-distance runners and sprinters. *Phys Sportsmed*. 2010; 38: 112-118
32. Hoogsteen J, Hoogeveen A, Schaffers H, Wijn PF, van Hemel NM, van der Wall EE. Myocardial adaptation in different endurance sports: an echocardiographic study. *Int J Cardiovasc Imaging*. 2004; 20: 19-26
33. Morganroth J, Maron BJ, Henry WL, Epstein SE. Comparative left ventricular dimensions in trained athletes. *Ann Intern Med*. 1975; 82: 521-524
34. Naylor LH, George K, O'Driscoll G, Green DJ. The athlete's heart: a contemporary appraisal of the 'Morganroth hypothesis'. *Sports Med*. 2008; 38: 69-90
35. Zdravkovic M, Perunicic J, Ristic M, Krotin M, Radovanovic S, Zaja M, Popovic-Lisulov D, Zdravkovic D. Is there cardiac remodeling in young teenage professional soccer players? *Eur J Echocardiogr*. 2010; 10: S177
36. Zdravkovic M, Perunicic J, Krotin M, Ristic M, Deljanin-Ilic M, Zdravkovic D, Milic N. Early left ventricular remodeling in highly trained adolescent football players. *Europrevent/Prevent Congress Abstract Book*. 2010; Paris, France, S 52
37. Zdravkovic M, Perunicic J, Krotin M, Ristic M, Vukomanovic V, Zaja M, Radovanovic S, Saric J, Zdravkovic D. Left ventricle remodeling in preadolescent footballers – the importance of adjustments to body surface area. *Eur J Echocardiogr*. 2010; 11: ii179
38. Zdravković M. Viral myocarditis – clinical issues and controversies: questions to be answered. *Medical Data*. 2010; 3: 179-186
39. Deljanin-Ilic M, Ilic S, Djordjevic D, Zdravkovic M, Ilic V. Evaluation of myocardial function in the presence of left ventricular hypertrophy in athletes and hypertensive patients. *Med Pregl*. 2008; 61: 178-182
40. Zdravkovic M, Babic M, Krotin M, Ristic M, Perunicic J, Zdravkovic D, Milinic N, Deljanin-Ilic M, Zaja M. Diastolic function in professional athletes-rowers. *Euroecho Abstract CD*, Lisbon, Portugal, 2007; p.S11-195
41. Caselli S, Di Pietro R, Di Paolo FM, Pisciocchio C, di Giacinto B, Guerra E, Culasso F et al. Left ventricular systolic performance is improved in elite athletes. *Am J Cardiol*. 2011; 108: 141-147
42. Caselli S, Di Paolo FM, Pisciocchio C, Di Pietro R, Quattrini FM, Di Giacinto B, et al. Three-dimensional echocardiographic characterization of left ventricular remodeling in Olympic athletes. *Eur J Echocardiogr*. 2011; 12: 514-519
43. Pelliccia A, Di Paolo FM, De Blasiis E, Quattrini FM, Pisciocchio C, Guerra E, Culasso F, Maron BJ. Prevalence and clinical significance of aortic root dilation in highly trained competitive athletes. *Circulation*. 2010; 122: 698-706
44. D'Andrea A, Cocchia R, Riegler L, Scarafie R, Salerno G, Gravino R, et al. Aortic root dimensions in elite athletes. *Am J Cardiol*. 2010; 105: 1629-1634
45. Wilhelm M, Brem MH, Rost C, Klinghammer L, Hennig FF, Daniel WG, et al. Early repolarization, left ventricular diastolic function, and left atrial size in professional soccer players. *Am J Cardiol*. 2010; 106: 569-574
46. D'Andrea A, Riegler L, Golia E, Cocchia R, Scarafie R, Salerno G, et al. Range of right heart measurements in top-level athletes: The training impact. *Int J Cardiol*. 2011; (Epub ahead of print)
47. D'Ascenzi F, Cameli M, Zacà V, Lisi M, Santoro A, Causarano A, Mondillo S. Supernormal diastolic function and role of left atrial myocardial deformation analysis by 2D speckle tracking echocardiography in elite soccer players. *Echocardiography*. 2011; 28: 320-326
48. Zdravkovic M, Krotin M. Right ventricular noncompacted cardiomyopathy - time for a new classification? *Chinese Medical Journal*. 2010; 122: 2920