

*Originalni članci/  
Original articles*

HORMONAL INFLUENCES IN A PATIENT  
WITH RELAPSING - REMITTING MULTIPLE  
SCLEROSIS. A 10-YEAR LONGITUDINAL  
MRI STUDY OF CORTICAL LESIONS

**Correspondence to:**

Assoc. Prof. **Denislava Deleva**, PhD  
Institute of Experimental Morphology,  
Pathology and Anthropology with  
Museum  
Department of Experimental Morphology  
Sofia 1113, Acad. G. Bonchev Str., bl. 25  
Tel: + 359 2 979 2397  
Fax: + 359 2 871 9007  
e-mail: denid2@excite.com

UTICAJI HORMONA KOD BOLESNICE SA  
RELAPSNO-REMITENTNOM MULTIPLE  
SKLEROZOM. 10-GODIŠNJA LONGITUDI-  
NALNA STUDIJA KORTIKALNIH LEZIJA  
MAGNETNOM REZONANCOM

Denislava D. Deleva, Vera Iv. Kolyovska,  
Borislav St. Sultanov/ Bulgarian Academy of Sciences

Institute of Experimental Morphology, Pathology and Anthropology with  
Museum Department of Experimental Morphology  
Sofia 1113, Acad. G. Bonchev Str., bl. 25

*Key words*

multiple sclerosis, pregnancy,  
sex hormones, MRI

*Ključne reči*

multiple skleroza, trudnoća,  
polni hormoni, magnetna rezonanca.

*Abstract*

Multiple sclerosis (MS) is one of the most common neurological disorders, which affects mainly women. MS causes neuronal lesions in the brain and spinal cord. Clinical studies were focused on the type, morphology and evolution of MS lesions on conventional MRI. The effect of sex hormones function on MS disease course and their relationship in pregnant women with MS is still unclear. The objective of this investigation was to show clinical significance of sex hormones in a patient with relapsing-remitting MS (RRMS) (before and during the pregnancy and after delivery) and their influence on disease course in a 10-year longitudinal MRI study. Our findings point out that during the long term remission period (7 years) there was no change observed in the MRI findings and no evidence for disease progression which suggests the possible role not only of the female sex hormones during and after pregnancy, but also of the conducted neuroprotective therapy.

Key words: multiple sclerosis, pregnancy, sex hormones, MRI

*INTRODUCTION*

Multiple sclerosis (MS) is a common demyelinating disorder of the central nervous system (CNS) and is considered to be multifactorial with an autoimmune component. There is growing evidence suggesting that hormones, including sex hormones, can affect and be affected by the immune system. MS affects females more than males. Higher levels of testosterone in men may partially account for the fact that women with MS outnumber men by 2-3 to 1. The levels of two important female sex hormones (estrogen and progesterone) are very high during pregnancy and that may suppress immune activity to some degree.

Myelination, the process in which oligodendrocytes coat CNS axons with a myelin sheath, represents an

important but poorly understood form of neural plasticity that may be sexually dimorphic in the adult CNS<sup>[1,2]</sup>. MS is characterized by intermittent or chronic damage to the myelin sheaths, focal inflammation and axonal degeneration. The present pharmacological treatment of MS is limited to the administration of immunomodulatory and anti-inflammatory drugs, which are only palliative and do not significantly slow down the disease progression. Agents that target different cell types in the CNS, protect axonal networks and stimulate the endogenous capacity of myelin repair are of specific need. Estrogens and progestins may be the basis for such a new therapeutic approach and could help protect against myelin loss. Both types of hormones have been shown to promote the viability of neurons and the formation of myelin<sup>[3]</sup>.

Sex hormones have major effects on brain and spinal neurons. The theory of hormones influencing inflammation and neuronal and glial function has been slowly unraveled. There is increasing evidence that estrogen, progesterone, and testosterone contain immune responses and influence damage repair in the nervous system. Hormones such as prolactin and vita-

Lately the importance to detect the hormonal changes in pregnant women with MS has grown. It is known that hormonal changes during pregnancy promote increased oligodendrocyte production in the maternal CNS. Remission of MS during this process led to hypothesize that remyelination is enhanced in the brain [1,2]. The researchers demonstrated that pregnant mice (animal model of MS) have an enhanced ability to remyelinate white matter lesions. The hormone prolactin regulates oligodendrocyte precursor proliferation and mimics the regenerative effects of pregnancy. What's unique about prolactin is that it promotes the formation of new oligodendrocytes – cells that produce myelin. Gregg et al. [1,2] suggest that prolactin may be used as a potential therapeutic agent for MS. A hormone produced during pregnancy could reverse some of the neurological damage associated with MS. This finding could help explain why women with MS suffer fewer symptoms during pregnancy. The authors suspected that rising levels of the hormone prolactin which promotes breast development and milk production might cause protective effect and might be used to treat people with MS [7].

The roles of progesterone (Pg), an immunomodulatory sex steroid, are poorly understood. Pg's immunomodulatory effects differ from those of estrogens and androgens. At pregnancy levels, Pg may suppress disease activity in MS [8]. During late pregnancy (third trimester) there is a decrease in MS disease activity due to the protective effect of testosterone [9].

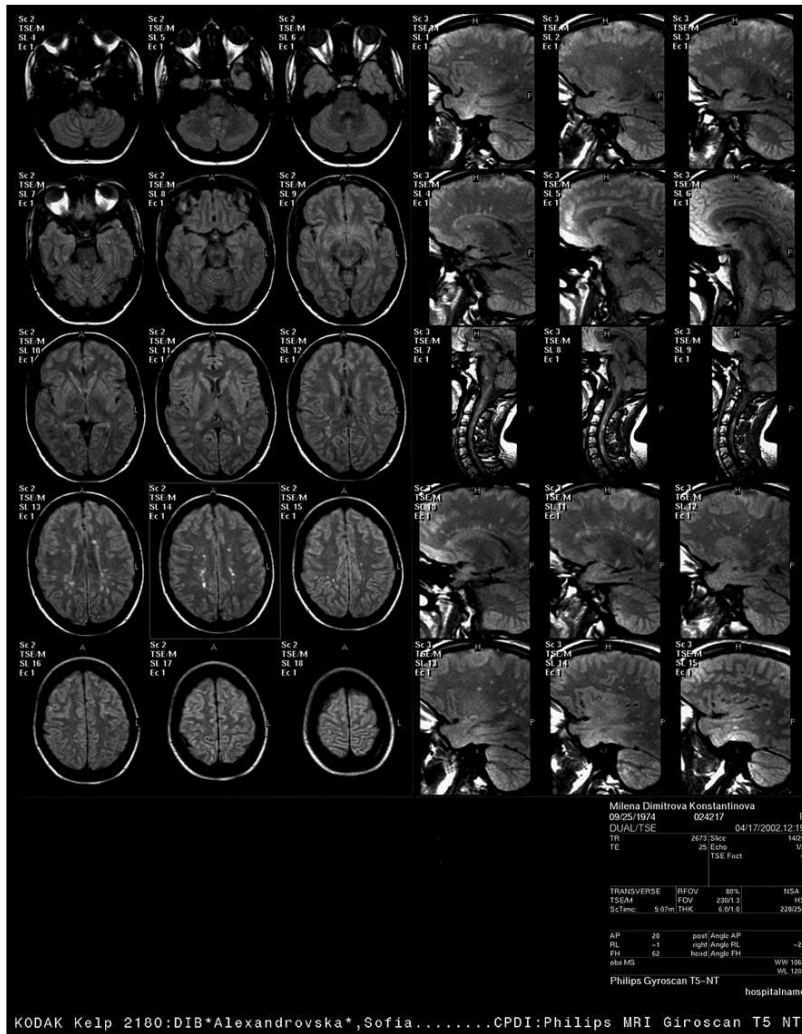


Figure 1.

min D, and more recently identified ones, such as leptin and gherlin, may be used to modulate the immune response and may also influence the course of MS [4]. The effect of female sex hormones is associated with hormonal alteration on the disease process. Sex steroids (particularly estrogen, androgen, and progesterone) also play an important role in neuroprotection following brain injury both in vivo and in vitro [5]. The role of male steroids in neuroprotection is less clear.

Prolactin (PRL) is a neuroendocrine peptide with potent immunomodulatory properties. Significantly higher prolactin levels in serum and cerebrospinal fluid (CSF) were found in female RRMS patients, but not in males. The elevated PRL levels could be the result of an increased predisposition of females to synthesize and release PRL [6].

MS causes neuronal lesions in the brain and the spinal cord. Hence, conventional magnetic resonance imaging (MRI) has played a unique role in the diagnosis and management of patients with MS. It is an established tool in the monitoring of disease evolution. Current techniques have allowed in vivo assessment of the heterogeneity of MS pathological features in focal lesions and in normal appearing tissues [10]. Calabrese et al. [11,12] assessed the occurrence, extent, and frequency of formation of cortical lesions in patients with PPMS (primary progressive multiple sclerosis), RRMS and SPMS (secondary progressive multiple sclerosis) and their relationship with cortical atrophy and disability progression after a 2- and 3-year longitudinal MRI study. They found that cortical lesions are a frequent finding in PPMS. The extent of such abnormalities is associated with the

extent of cortical atrophy and clinical disability. In patients with RRMS and SPMS such lesions accumulate over time and are associated with disability progression. The quantification of cortical lesions might represent an additional useful non-clinical tool to monitor MS evolution.

The aim of this investigation was to show clinical significance of sex hormones in a patient with RRMS and their influence on the disease course in a 10-year

eventually was restarted 2 weeks postpartum with Copaxon, Milgamma N and Nivalinã. From 2005 until present (year 2012) the patient has been in remission. Pre - and postnatal development of her child was normal. The study was conducted in compliance with the principles of the Declaration of Helsinki 1964 and its amendments (Tokyo 1975, Venice 1983, Hong Kong 1989).

**RESULTS AND DISCUSSION**

In the current investigation, clinical studies were focused on the type, morphology and evolution of MS lesions using conventional MRI in a patient with RRMS before pregnancy (Fig.1) and after delivery (Fig.2).

**MRI results from a 10-year longitudinal study**

**Year 2002: MRI brain and spinal cord in axial and sagittal planes**

Multiple, predominantly small hyperintense foci in the brain white matter located bilaterally periventricularly and subcortically towards the convexity, in the basal ganglia and capsula interna, in all parts of corpus callosum, in the cerebellum, pons, craniospinal junction and along the cervical medulla spinalis. These changes are usually seen in a demyelinating process such as MS with cranial and spinal involvement with corresponding clinical and immunologic evidence (Fig.1).

**Year 2005: Brain MRI in axial plane and cervical spine in sagittal plane**

Compared to previous MRI study from 2002 – no dynamic changes; no evidence of disease progression based on “lesion load on T2”.

**Year 2009: MRI brain and spinal cord in axial and sagittal planes with gadolinium contrast enhancement (0,1 mmol Gd/kg)**

Compared to previous MRI findings from 2005 – no evidence of disease progression based on “lesion load on T2”. Intact blood-brain and blood-spinal fluid barriers (Fig.2).

**Year 2011: MRI brain: T2 imaging in axial and sagittal planes, FLAIR axial and T1 sagittal planes**

Subarachnoid space and brain ventricles – normal. Supra- and subtentorial hyperintense foci documented previously on T2 and FLAIR imaging from 2009 persist. Hyperintense foci noted in cervical cord at C2 level. Pontocerebellar angles appear normal. Brain ventricular system – normal shape, size and location. No evidence of MRI findings progression compared to MRI study from 2009 – cerebrospinal demyelinating process.

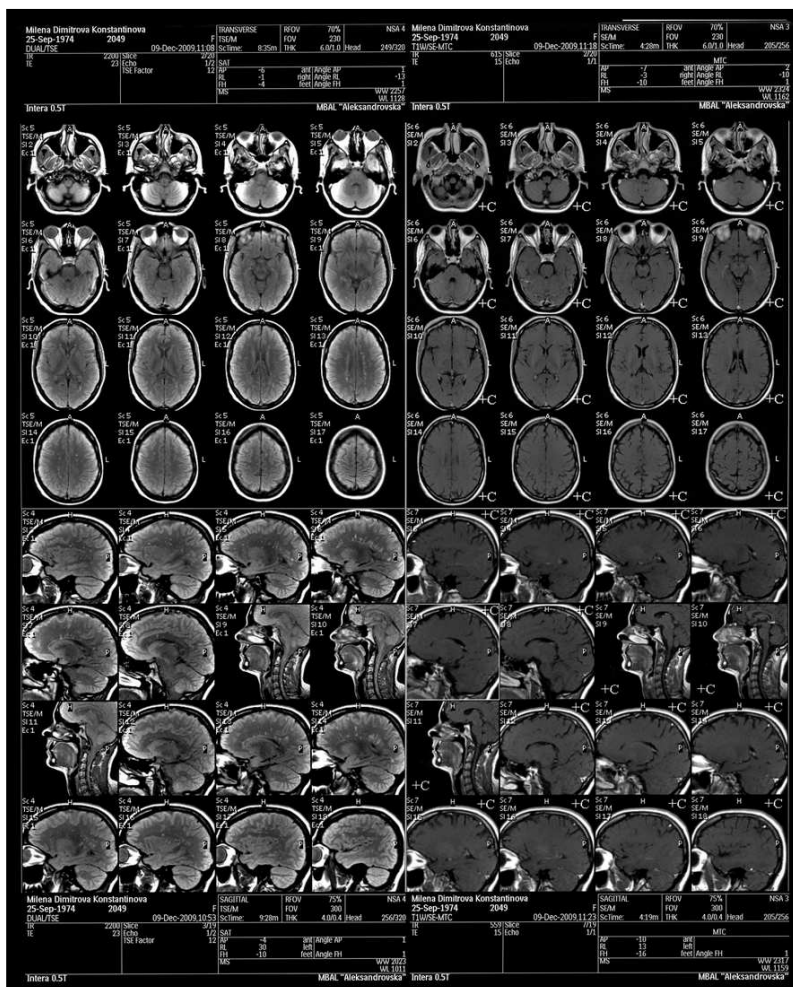


Figure 2.

longitudinal MRI study of brain and spinal cord (before and during the pregnancy and after delivery). Similar studies have not been performed so far. MRI was designed to assess the frequency, extent, and rate of cortical lesions formation in RRMS and their relationship with T2 lesion volume, white matter atrophy, and disability.

**MATERIALS AND METHODS**

MRI was performed in a patient at age 28 (year 2002) with a confirmed clinical diagnosis of MS, relapsing-remitting variant, satisfying McDonald MRI criteria, with assigned level 1,5-2 Kurtzke Disability Status and no contraindications for therapy with Copaxon. She was found to be pregnant at age 34 (year 2007). From conception until delivery she had an interruption in her usual neuroprotective therapy, which

The fact that there is no progression on MRI imaging findings from 2005 until 2012 based on brain "T2 lesion load" suggests the protective role not only of the conducted therapy until pregnancy onset, but also of the female sex hormones during pregnancy. Our assumptions coincide with those by Paavilainen et al. [13] who report that the relapse frequency of MS decreases during pregnancy.

Moreover, our previous findings of significantly elevated titers of serum IgM antibodies to GM1 and GD1a gangliosides of the same patient before pregnancy suggest immune-mediated demyelination and neu-

rodegeneration as an underlying pathogenetic mechanism in MS. Unchanged IgM antiganglioside antibodies titers during long-term postpartum disease period (in comparison with healthy subjects) support the concept of possible beneficial effect of pregnancy on disease progression [14,15].

### Apstrakt

Multiple skleroza (MS) je jedan od najčešćih neuroloških poremećaja, koji uglavnom pogađa žene. MS uzrokuje pojavu lezija neurona u mozgu i kičmenoj moždini. Kliničke studije se fokusiraju na tipove, morfologiju i revolucije lezija viđenih na slikama na konvencionalnoj magnetnoj rezonanci (MR). Efekti polnih hormona na tok bolesti i njihov odnos kod trudnih žena sa MS je još uvek nedovoljno jasan. Cilj ovog istraživanja je bio da se pokaže klinički značaj polnih hormona kod bolesnice sa relapsno-remitentnom MS (RRMS) (pre i za vreme trudnoće i posle porođaja) i njihov uticaj u 10-godišnjoj longitudinalnoj studiji u kojoj je korišćena MR. Naša istraživanja pokazuju da tokom dužeg perioda remisije (7 godina) nisu uočene promene na MR i nije bilo znakova progresije bolesti, što ukazuje na moguću ulogu ne samo ženskih polnih hormona za vreme i nakon trudnoće, već i sprovedene neuroprotektivne terapije.

### REFERENCES

1. Gregg C, Shikar V, Larsen P, Mak G, Chojnacki A, Yong V, Weiss S: White matter plasticity and enhanced remyelination in the maternal CNS. *J Neurosci.* 2007; 27, 8: 1812-1823.
2. Gregg C: Pregnancy, prolactin and white matter regeneration. *J Neurol Sci.* 2009;285, 1-2: 22-27.
3. El-Etr M, Ghoumari A, Sitruk-Ware R, Schumacher M: Hormonal influences in multiple sclerosis: new therapeutic benefits for steroids. *Maturitas.* 2011; 68, 1: 47-51.
4. Shuster E: Hormonal influences in multiple sclerosis. *Curr Top Microbiol Immunol.* 2008; 318: 267-311.
5. Liu M, Kelly M, Herson P, Hum P: Neuroprotection of sex steroids. *Minerva Endocrinol.* 2010; 35: 127-143.
6. Markianos M, Koutsis G, Evangelopoulos M, Mandellos D, Sfagos C: Serum and cerebrospinal fluid prolactin levels in male and female patients with clinically-isolated syndrome or relapsing-remitting multiple sclerosis. *J Neuroendocrinol.* 2010;22,6:503-508.
7. Khamsi R: Canadian mouse study shows hormone associated with pregnancy may reverse MS. *J Neurosci.* 2007; 27, 8: 1812-1823.
8. Hughes G: Progesterone and autoimmune disease. *Autoimmun Rev.* 2011; Dec.13. ŠEpub ahead of print.
9. Voskuhl R: Gender issues and multiple sclerosis. *Curr Neurol Neurosci Rep.* 2002; 2, 3: 277-286.
10. Filippi M, Rocca M: MR imaging of multiple sclerosis. *Radiology.* 2011;259,3:659-681.
11. Calabrese M, Rocca M, Atzori M, Mattisi I, Bernardi V, Favaretto A, Barachino L, Romualdi C, Rinaldi L, Perini P, Gallo P, Filippi M: Cortical lesions in primary progressive multiple sclerosis: a 2-year longitudinal MR study. *Neurology.* 2009; 72, 15: 1330-1336.
12. Calabrese M, Rocca M, Atzori M, Mattisi I, Favaretto A, Perini P, Gallo P, Filippi M: A 3-year magnetic resonance imaging study of cortical lesions in relapse-onset multiple sclerosis. *Ann. Neurol.* 2010; 67, 3: 376-383.
13. Paavilainen T, Kurki T, Farkkila M, Salonen O, Parkkola R, Airas L: Lower brain diffusivity in postpartum period compared to late pregnancy: result from a prospective imaging study of multiple sclerosis patients. *Neuroradiology.* 2011; Dec. 13. ŠEpub ahead of print.
14. Zaprianova E, Deleva D, Kolyovska V, Sultanov B: Clinical significance of serum antiganglioside antibodies in multiple sclerosis. *Acta morphol et anthropol.* 2011; 17: 19-24.
15. Deleva D, Kolyovska V, Sultanov B: Multiple sclerosis and pregnancy: disease biomarkers. *Compt Rend Bulg Acad Sci.* 2012 (in press).