

*Originalni članci/
Original articles*

RAT CHOROID PLEXUS:
MORPHOMETRIC CHARACTERISTICS

Correspondence to:

Valentina K. Ormandzhieva, PhD
E-mail Address:
vormandzhieva@yahoo.com
Bulgarian Academy of Sciences
Institute of Experimental Morphology and
Anthropology with Museum
Department of Experimental Morphology
Bulgarian Academy of Sciences
Acad. G. Bonchev Str., Bl. 25
1113 Sofia, BULGARIA
Tel.: +359 2 979 3630;
fax: +359 2 871 9007

Valentina K. Ormandzhieva

Bulgarian Academy of Sciences; Institute of Experimental Morphology
and Anthropology with Museum Department of Experimental
Morphology

Ključne reči/Key words

rat choroid plexus, light and dark
epithelial cells, morphometry,
development

Abstract

In the present study were carried out morphometrical investigations of the rat choroid during development. Morphometrical data of the rat choroid plexus provide evidence that light and dark epithelial cells finish their differentiation on 30 days postnatum. The cell area of the dark epithelial cells is smaller than the cell area of the light cells and this difference retains up to 22 months. The relative part of the dark epithelial cells increases during ontogenesis and at 13 months it is larger than the relative part of the light cells. This tendency concurs with ultrastructural data of decreased functional activity of the choroid plexus with age, and may be correlated with the age changes of the rat choroid plexus epithelial cells. Changes of the epithelial cells during development suggest that dark and light cells are modulations of the same basic cells with possible functional differentiation starting from 17 days postconception and continue to 22 months.

INTRODUCTION

The choroid plexuses are specialized highly vascular anatomical structure which protrude into the lateral ventricle, as well as in the third ventricle and fourth ventricle. The surface of the choroid plexus consists of numerous villi each covered with single layer of epithelial cells surrounded by vascular connective tissue cells [1, 2, 3]. These cells are generally considered to be modified ependymal cells with epithelial cell characteristics and referred to as choroidal epithelial cells.

Plexus choroideus participates in the formation of cerebrospinal fluid (CSF) and in the transportation of the substances from the blood, to the CSF and vice versa [4]. As a secretory source of vitamins, peptides and hormones for neurons, the choroid plexus provides substances for brain homeostasis [5].

Most blood vessels in the plexus choroideus are wide-calibers (approximately 15µm) capillaries with thin fenestrated endothelial walls and bridging diaphragms overlying the fenestrations [6]. Light and dark choroidal epithelial cells were identified by Wislocki and Ladman [7] and they suggested that the difference in the cell density reflected differ-

ent stages in the secretory cycle of the choroidal epithelium. Arginine vasopressin (AVP) decreases CSF formation rate and choroidal blood flow, and AVP also increases by more than twofold the number of dark epithelial cells and possibly dehydrated but otherwise morphologically normal choroid epithelial cells in adult rat choroid plexus [8].

Purpose of the present study is an investigation of morphometrical changes of the rat choroid plexus epithelial cells during development from 17 days postconception to 22 months postnatum.

MATERIAL AND METHODS

Wistar rats (n=60) aged 17 and 20 days postconception, 5, 15, 30, 45 and 60 days postnatum and 4, 7, 10, 13 and 22 months were used. The animals were fixed by immersion [9] and by intracardial perfusion [10]. The choroid plexuses were embedded in Durcupan and examined with JEOL JEM 1200EX transmission electron microscope. We obtained morphometric data from the light microscope Carl Zeiss Jena at 1000X magnification using a square grid system (625 test point) [11] calibrated for linear measurement in µm and area measurement in µm². All values were expressed as mean ±

SEM, and statistically analyzed by Student t-test using statistical package (STATISTICA, ver.6, Stat-Soft Inc., 2001).

The animal experiments were performed in accordance with animal protection guidelines approved by the Ethics Committee for experimental animal use at IEMAM - BAS.

RESULTS

In the present study on the rat choroid plexus during development it was established that the nuclear, cytoplasmic and cell area of the dark epithelial cells is smaller than the same parameters of the light epithelial cells during the whole investigated period (Fig. 1.). The nuclear area of the light

cells increased from 17 days postconception to 5 days postnatum and the nuclear area of the dark cells increased from 17 to 20 days postconception. The cytoplasmic and cell area of the light and dark cells increased more significantly from 17 days postconception to 5 days postnatum. The height of the epithelial cells was two times more than the cell width during the embryonal period of the development (Fig. 2.). The height of the light epithelial cells was $19.59 \pm 3.1 \mu\text{m}$ and the width $- 9.61 \pm 2.5 \mu\text{m}$, and the height of the dark epithelial cells was $15.5 \pm 3.2 \mu\text{m}$ and the width $- 7.0 \pm 2.0 \mu\text{m}$ on the 17th day postconception. The cell height of the light and dark epithelial cells decreased significantly from

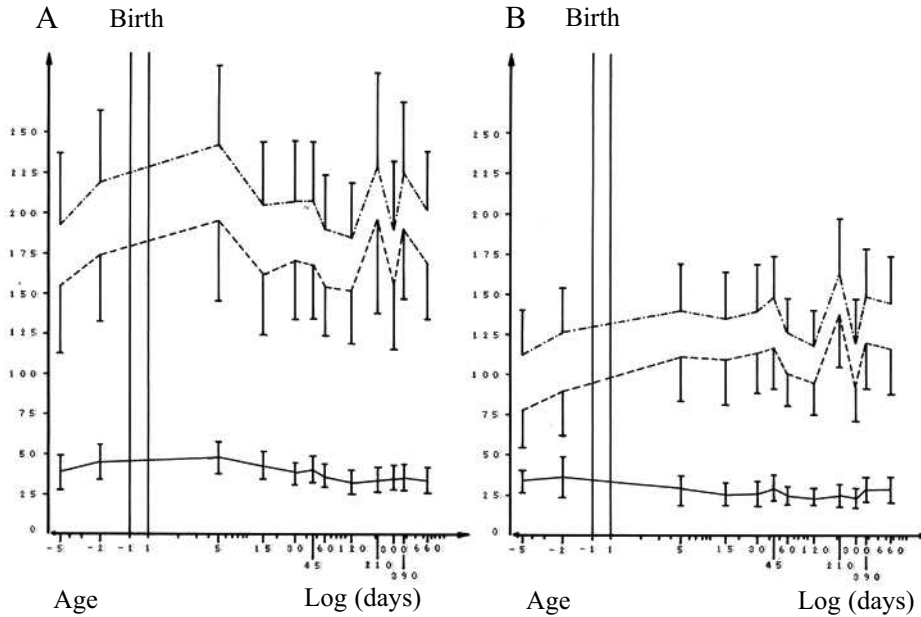


Fig. 1. Morphometric analysis of light (A) and dark (B) epithelial cells of rat choroid plexus during development. Nuclear (-), cytoplasmic (---) and cell (· · ·) area

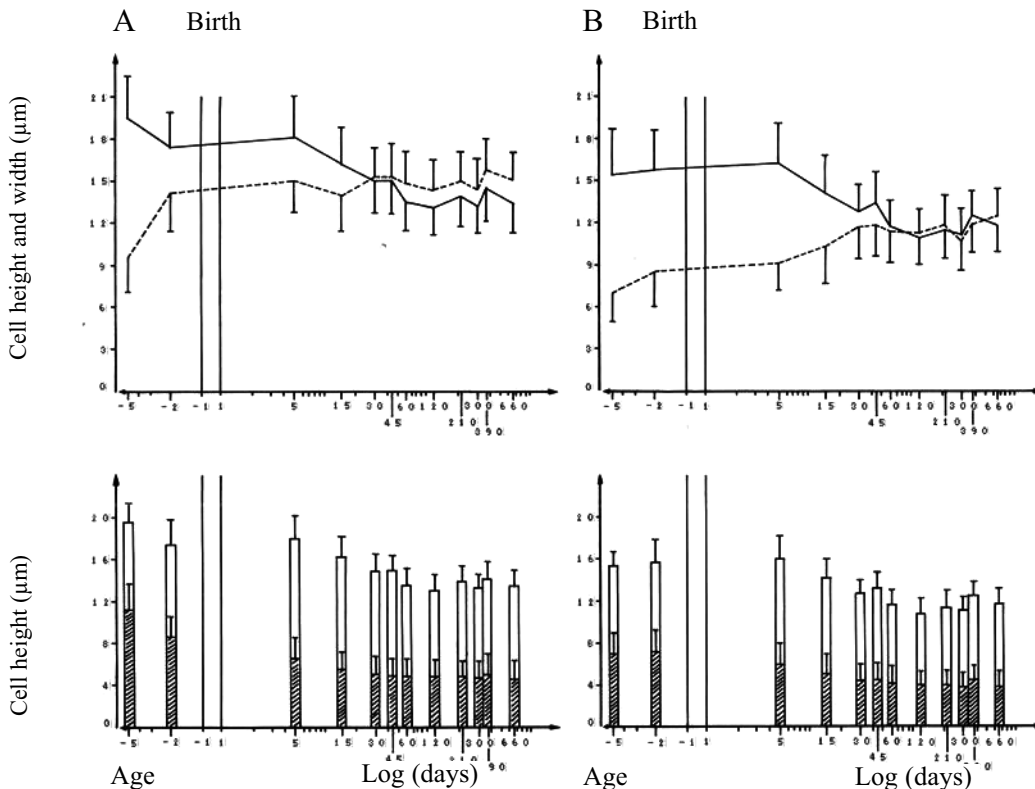


Fig. 2. Morphometric analysis of the light (A) and dark (B) epithelial cells of rat choroid plexus during development. Cell height (continuous line), cell width (dotted line), height from the apical part of the epithelial cell to the centre of the nucleus (white) and height from the centre of the nucleus to the basal part (patterned).

17 days postconception, where as the cell width during the same period increased significantly. These parameters became equal on the 30th - 45th day postnatum and this tendency stayed constant up to 22 months. The height and width of the light cells were average 15 μm, and those of the dark cells - 11 μm. The nuclear localization of the light epithelial cells was apical and the dark epithelial cells - apical-central during embryonal period of the development. The nuclear localization of the light and dark epithelial cells

of the light cells at an average 35% and this difference is preserved to 22 months. During the first period of development (17-20 days postconception) the cell height of light and dark epithelial cells is bigger than the cell width by 50.94% (light cells) and by 54.84% (dark cells). During the second period (20 days postconception - 15 days postnatum) the height of the light cells is bigger than the width by 17.17%, on an average, and of the dark cells by 39.36%. The cell height and width of light (height - 15.06 μm, width - 15.23 μm) and

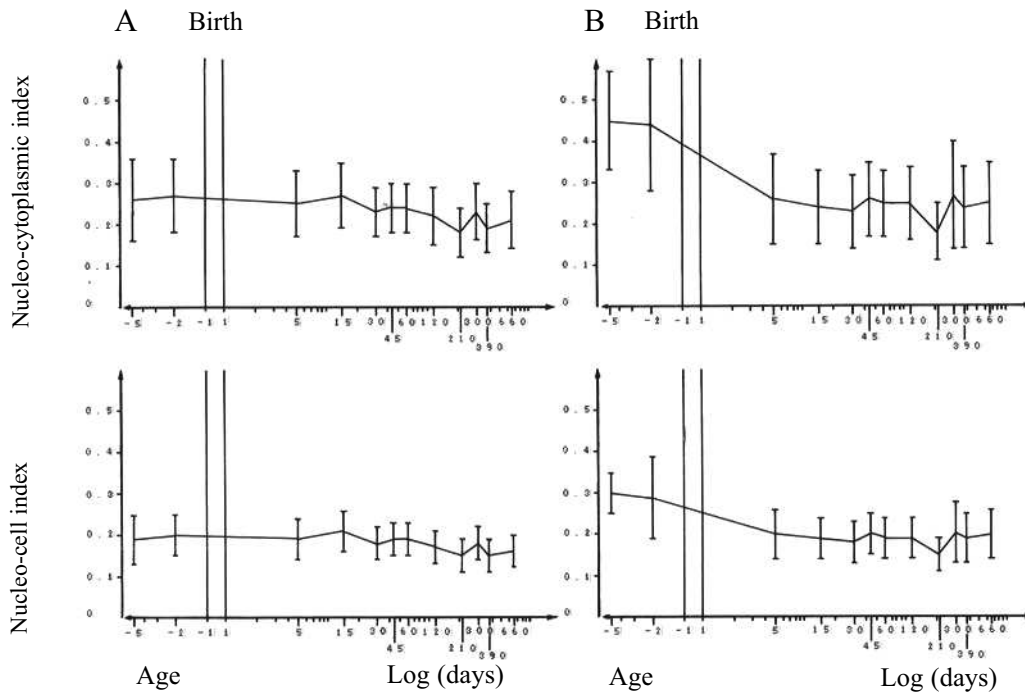


Fig. 3. Morphometric analysis of light (A) and dark (B) epithelial cells of rat choroid plexus during development. Nucleo-cytoplasmic (Sn/Sc) and nucleo-cell (Sn/Scell) indices

was basal at the 15 days postnatum and stayed constant from 30 days to 22 months.

In the second graph (Fig. 3.) are presented the nucleocytoplasmic index (a correlation of the nuclear and cytoplasmic area) and nucleocell index (a correlation of the nuclear and cell area) of the light and dark epithelial cells during development. The nucleocytoplasmic and nucleocell index of the dark epithelial cells decreased significantly with age from 0.45 ± 0.12 and 0.30 ± 0.05 on the 17th day postconception to 0.26 ± 0.1 and 0.20 ± 0.06 five days after birth. The same parameters of the light epithelial cells decreased much smaller with age from 0.26 ± 0.1 and 0.19 ± 0.06 on the 17th day postconception to 0.23 ± 0.06 and 0.18 ± 0.04 30 days after birth. There were no significant changes in the nucleocytoplasmic and nucleocell index of the light and dark epithelial cells 45 days after birth up to 22 months.

The relative part of the light cells (Fig. 4.) decreased during development and at the age of 22 months was 33.1%, whereas the relative part of the dark cells increased and at the age of 22 months was 66.9%.

DISCUSSION

The present morphometrical study of the rat choroid plexus during development gives evidence that light and dark epithelial cells finish their differentiation 30 days postnatum and pass through three-phase development. The cell area of the dark epithelial cells is smaller than the cell area

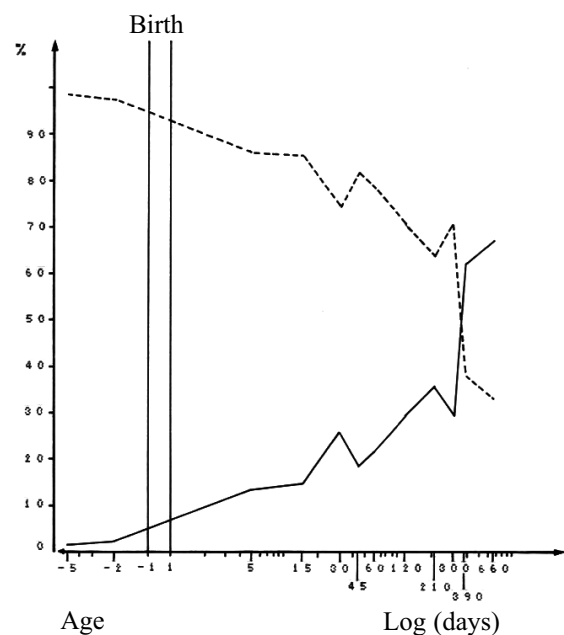


Fig. 4. Relative part of the light (---) and dark (-) epithelial cells of the rat choroids plexus during development

dark (height - 12.81 μm, width - 11.74 μm) epithelial cells become equal during the third period (30 days postnatum) and the cells pass into cuboidal. Changes of the nuclear, cytoplasmic and cell area of the light and dark epithelial cells from 17 days postconception to 15 days postnatum are

proceeded simultaneously with the ultrastructural data of glycogen accumulation [1, 12]. The morphometrical parameters of the light and dark epithelial cells stayed constant without significant changes from 45 days postnatum to 22 months, as the average nuclear and cell area of the light cells is $35.8 \mu\text{m}^2$ and $204.5 \mu\text{m}^2$, and of the dark cells - $25.9 \mu\text{m}^2$ and $137.2 \mu\text{m}^2$ [13].

Changes of the nuclear localization of the epithelial cells from apical during embryonal period of development to basal on the 15th day postnatum may be correlated with the glycogen accumulation and consumption during the same period [14]. The nucleo-cytoplasmic interactions of the epithelial cells are more expressive during the embryonal and earlier postnatal period of development in comparison with the later period of ontogenesis. The nucleo-cytoplasmic and nuclei-cell index of the dark cells decreased by 42% and respectively by 33% from 17 days postconception to 5 days postnatum, and the nucleo-cytoplasmic index of the light cells decreased by 3.8%. The nucleo-cytoplasmic index of the dark cells is bigger than that of the light cells on the 17th and 20th day postconception. It has been suggested that the index changes may be related with more expressive nucleo-cytoplasmic interaction of the dark epithelial cells in relation to light epithelial cells [15].

The relative part of the dark cells increased during the whole period of development and after the age of 13 months remains higher (61.97%) than the relative part of the light cells (38.03%). This tendency concurs with ultrastructural data of decreased functional activity of secretion, absorption and transport of substances of the choroid plexus with age and could play a part in the changes of the central nervous system [16].

In *conclusion* it can be pointed out that the observed morphometrical changes of the rat choroid plexus epithelial cells during development suggest that dark and light cells are modulations of the same basic cells with possible functional differentiation starting from 17 days postconception and continue to 22 months. The cell area of the dark epithelial cells is smaller than the cell area of the light epithelial cells from 17 days postconception and this difference is preserved to 22 months.

REFERENCES

- Ormandzhieva VK: Electronmicroscopical and hystometrical investigation of the rat choroid plexus during development and after experimental conditions. PhD Thesis, Sofia, 1993.
- Ormandzhieva VK: Morphometric analysis of epitheliocytes in the choroid plexus of brain ventricles in rat ontogenesis. *Morfologija* (Saint Petersburg, Russia). 2003; 124, 6: 30-33.
- Emerich DF, Vasconcellos AV, Elliott RB, Skinner SJM, Borlongan CV: The choroid plexus: function, pathology and therapeutic potential of its transplantation. *Expert Opin Biol Ther*. 2004; 4, 8: 1-11.
- Spector R: Nature and consequences of mammalian brain and CSF efflux transporter: four decades of progress. *J Neurochem*. 2010; 112:13-23.
- Johanson CE, Duncan JA, Klinge PM, Brinker T, Stopa EG, Silverberg GD: Multiplicity of cerebrospinal fluid functions: New challenges in health and disease. *Cerebrospinal Fluid Research*. 2008; 5:10.
- Milhorat TH: Structure and function of the choroid plexus and other sites of cerebrospinal fluid formation. *Intern Rev Cytol*. 1976; 47: 225-88.
- Wislocki GB, Landman AJ. In: The cerebrospinal fluid. The fine structure of the mammalian choroid plexus (eds Wolstenholme GEW, O'Connor CM). Boston, Brown, 1958, pp. 55-79.
- Johanson CE, Preston JE, Chodobski A, Stopa EG, Smydynger-Chodobska J, McMillam PN: AVP V1 receptor-mediated decrease in Cl⁻ efflux and increase in dark cell number in choroid plexus epithelium. *Amer J Physiol*. 1999; 276: C82-C90.
- Zaki W: Ultrastructure of the choroid plexus and its development in the mouse. *Z mikrosk und Forsch*. 1981; 95: 919-935.
- Karnovsky MJ: A formaldehyde-glutaraldehyde fixative of high osmolarity for use in electron microscopy. *J Cell Biol*. 1965; 27: 137A.
- Weibel ER: Selection of the best method in stereology. *J Microsc*. 1974; 100: 261-269.
- Tennyson VM, Papas GD: The fine structure of the choroid plexus: adult and developmental stage. In: Lajta A., Ford D.H. (eds.): *Prog in Brain Res.*, 1968; 29: 63-85.
- Ormandzhieva VK: Ageing choroid plexus and experimental models: morphometrical study. *Compt rend Acad bulg Sci*. 2003; 56, 7: 105-110.
- Sturrock RR: A morphological study of the development of the mouse choroid plexus. *J Anat*. 1979; 129: 777-793.
- Ormandzhieva VK: Morphometrical study of the nucleo-cytoplasmic index, cell height and width and nuclear localization of the light and dark epithelial cells of rat choroid plexus during development from 17 days postconception to 22 months postnatum. *Compt rend Acad bulg Sci*. 2004; 57, 8: 87-92.
- Serot JM, Foliguet B, Bene MC, Faure GC: Choroid plexus and ageing in rats: a morphometric and ultrastructural study. *Eur J of Neurosci*. 2001; 14: 794-798.