

*Originalni članci/  
Original articles*

BISPHOSPHONATE-ASSOCIATED  
OSTEONECROSIS OF THE JAW.

*Presentation of 15 cases*

BIFOSFONATNA TERAPIJA I  
OSTEONEKROZA VILICA.

*Prikaz 15 slučajeve*

**Correspondence to:**

Associate Professor

**Dr Mario Vicente Barrero**

Calle Alcalde Henríquez Pitti 13, 1º izq

35400-Arucas SPAIN

Telephone 928602951

Fax 928634736

E-mail: mmvicenteb@gmail.com

Sacramento Bocanegra-Pérez<sup>1</sup>, Mario Vicente-Barrero<sup>2</sup>,  
Ariadna López-Márquez<sup>3</sup>, Manuel Sosa-Henríquez<sup>4</sup>,  
Milan Knezevic<sup>5</sup>, José Maria Castellano-Navarro<sup>6</sup>,  
José Maria Limiñana-Cañal<sup>7</sup>

Complejo Hospitalario Universitario Insular Materno Infantil, Las Palmas de Gran Canaria, Spain. Universidad de Las Palmas de Gran Canaria. Department of Medical and Surgical Sciences

<sup>1</sup> Physician, specialist in Stomatology <sup>2</sup> Doctor in Medicine, specialist in Stomatology. Associate Professor at the University of Las Palmas, Grand Canary Island MD, DDS, PhD <sup>3</sup> Dentist <sup>4</sup> Professor of General Pathology at the University of Las Palmas, Grand Canary Island. Unit of Bone Metabolism.

<sup>5</sup> Doctor in Medicine specialist in Oral and Maxillofacial Surgery

<sup>6</sup> Physician and Dentist <sup>7</sup> Professor of Statistics at the University of Las Palmas, Grand Canary Island

*Key words*

bone metastasis, jaw, osteoporosis,  
osteonecrosis, prevention

*Ključne reči*

metastaze u kostima, vilica, osteoporoza,  
osteonekroza, prevencija.

*Abstract*

**Background:** Osteonecrosis of the jaw (ONJ) is a newly emerging complication of bisphosphonate (BP) therapy, first described in 2003 and undetected in previous clinical trials. The aim of this study was to evaluate the clinical characteristics of 15 patients with bisphosphonate-related osteonecrosis of the jaw and to assess different treatment strategies.

**Method:** We studied 15 ONJ cases selected according to the criteria of the American Association of Oral and Maxillofacial Surgeons. The type of BP, route of administration, co-morbidities, clinical presentation and results of diagnostic tests were analyzed in this study.

**Results:** 12 women and 3 men of 60 years of age on average were included. Three of them had been under oral BP treatment and twelve of them, under intravenous (IV) BP treatment. The average treatment duration was 29.8 months for IV BPs and 87 months for oral BPs. Most of the included cases were associated to the use of zoledronate (80%). Breast cancer was the most frequent underlying disease (40%). Jaw was the most frequent location of osteonecrosis (73,3%). Tooth exodontia was the most frequent triggering factor (66,6%).

**Conclusion:** ONJ is a condition that mainly affects patients in advanced ages. It is important to individualize each patient by evaluating the corresponding administered BP, route of administration – IV or oral – treatment duration, administered doses, primary disease and possible concomitant diseases or treatments. ONJ diagnosis is mainly based on clinical findings. Prevention appears to be the best strategy for addressing this condition.

*INTRODUCTION*

Bisphosphonates (BPs) are synthetic analogues of the naturally occurring inorganic pyrophosphate, with a high affinity for calcium. Because of this characteristic, BPs are deposited into the mineralized bone matrix for long periods of time [1]. All of the BPs share a common chemical struc-

ture, consisting of a carbon atom bond to two phosphate groups (P-C-P), whose negative charge accounts for the high affinity of these molecules for the bone tissue. Their potency of action is based on the side chains bound to the nucleus. The presence of nitrogen compounds in these chains confers higher activity to the BP molecule [2].

Although their action mechanism is not completely understood, it is known to be based on the ability of the BP molecules to bind hydroxyapatite, thus inhibiting osteoclastic bone resorption without interfering with bone formation and mineralization [3]. The antiosteoclastic effect is thus a consequence of both: arresting the differentiation of common precursor cells (hematopoietic stem cells) and promoting apoptosis of mature osteoclasts [2]. Furthermore, BPs antagonize bone calcium release induced by tumor cell-produced stimulating factors [3]. These actions may potentially contribute to inhibit bone resorption and to improve bone mass [1]. Certain BPs, particularly the most recently developed and potent ones, which incorporate nitrogen into their molecular structures, have inhibitory effects upon tumor cell proliferation and angiogenesis [3,4].

Intravenous (IV) BPs are primarily used for treating oncologic patients – including patients with hypercalcemia of malignancy or bone metastases in the context of solid tumors such as those of breast, prostate or lung cancer – and for managing lytic lesions in the setting of multiple myeloma [5-9]. They are effective in preventing and reducing skeletal complications such as severe bone pain, fractures, or compression of the spinal cord [10]. Although not found to improve survival of oncologic patients, these drugs substantially enhance their quality of life, particularly that of patients with advanced cancer involving the skeletal system. [11]. In August 2007 the US Food and Drug Administration approved the use of a single annual dose of zoledronic acid (Aclasta®) to treat post-menopausal osteoporosis [12-13].

Orally administered BPs are poorly absorbed (below 1%; even less if the patient has failed to fast) and have about 1 hour half-life in plasma, with stable incorporation into bone of about 20% of the absorbed dose. Their half-life in bone is longer than 10 years and they are excreted unmetabolized with the urine [2]. They are primarily indicated to treat osteoporosis [14-15] either emerged in the context of other diseases such as inflammatory bowel disease or primary biliary cirrhosis, or resulting from medication (most commonly steroids) or menopause [16]. Furthermore, they are used to treat a variety of less common conditions such as Paget's disease of bone, and osteogenesis imperfecta of childhood [11].

In 2003, a newly emerging complication of BP therapy, undetected in previous clinical trials, was described for the first time [17]. This complication, called osteonecrosis of the jaw (ONJ), is now defined by the presence of exposed bone in the mouth which fails to heal after appropriate intervention over a period of 6 or 8 weeks. In the early stages, no radiographic manifestations can be seen. Patients are usually asymptomatic but may develop severe pain because the necrotic bone becomes secondarily infected after being exposed to the oral environment. The osteonecrosis is often progressive and may lead to extensive areas of bony exposure and dehiscence. This condition appears to be caused by a combination of deficient vascular supply and deficient bone remodeling and regeneration. Its onset has been associated to risk factors such as: cancer diagnosis, concomitant treatments (chemotherapy, head and neck radiotherapy or corticosteroid therapy) and situations of comorbidity (anemia, coagulopathy, infection, preexisting oral disease) [18].

These findings suggest that underlying associated circumstances could determine the development of this condition in some patients while not in others. Here we describe and evaluate 15 cases of BP-treated patients who developed ONJ with the aim of gaining deeper insight into this recently emerging entity, by analyzing what are the diseases where this complication most frequently occurs, the age of onset, the BP-type most frequently inducing ONJ, the possible dose- or time-dependency, the clinical manifestations, the current treatment strategies and the possible benefits of discontinuing BP treatment upon onset of ONJ.

## MATERIALS AND METHOD

This study involved evaluation of patients with clinical signs compatible with ONJ, who were referred to the Service of Stomatology and Oral and Maxillofacial Surgery, of the University Hospital-Maternity Ward of the Grand Canary Island, between September 2006 and October 2007. These patients had been referred from the Departments of Oncology Hematology, Bone Metabolism or Palliative Care of the University Hospital-Maternity Ward.

Patients were selected according to the criteria established by the American association of Oral and Maxillofacial Surgeons (AAOMS) [19]: 1. Patient under current or previous BP treatment; 2. Exposed necrotic bone in the maxillofacial region persisting for more than 8 weeks; 3. No previous history of radiation therapy to the jaws. Patients with neoplastic involvement of the maxillae were excluded.

The information was prospectively gathered through interviews and clinical examinations previous to complementary tests and review of the medical records. Data on the type of BP used, route of administration, co-morbidities, clinical presentation, underlying diseases and results of diagnostic tests were recorded.

## RESULTS

The study included a total of 15 patients: 12 women (80%) and 3 men (20%), aged 60 years on average (range 41-82) with the following underlying diseases: osteoporosis in 2 patients (13,3%); rheumatoid arthritis in 1 patient (6,6%); and oncologic diseases in 12 patients (80%) who were under anti-neoplastic treatment, some of them (66,6%) also under concomitant treatment with intermittent steroid cycles. The oncologic patients included cases of: breast cancer (40%), multiple myeloma (13,3%), rectal cancer (6,6%) and prostate cancer (13,3%). One of them (6,6%) had coexisting prostate cancer and multiple myeloma (Table I).

The administered BPs and corresponding average doses were as follows: 9 patients (60%) were treated only with zoledronic acid (Zometa®), in an average total dose of 95,5 mg (range 56-132); 3 patients (20%) were treated only with oral alendronate sodium (Fosamax®) in an average dose of 25.350mg (range 8.960-51.970); 2 patients (13,3%) were treated with pamidronate disodium (Aredia®) in an average dose of 1.935 mg (range 1.080-2.790), subsequently substituted by zoledronic acid, in an average dose of 140 mg (range 136-144); and 1 patient (6,6%) was treated with zoledronic acid in a dose of 64mg, subsequently substituted by ibandronic acid (Bondronat®) in a dose of 19.500mg. The mean duration of treatment was 29.8 months (14-65) for

Table I. Case descriptions

Patient N°	Sex	Age	Diagnosis	Bisphosphonate	Adm route	Dose (mg)	Frequency (days)	Total dose administered (mg)	Triggering Factor	Osteonecrosis location
1	woman	56	Breast Neoplasia	Zoledronate	IV	4	28	128	Exodontia	Jaw
2	man	54	Prostate Neoplasia	Zoledronate	IV	4	28	92	Unknown	Jaw
3	woman	73	Breast Neoplasia	Zoledronate	IV	4	28	132	Multiple exodontias	Maxillary
4	woman	69	Rheumatoid arthritis	Alendronate	Oral	70	7	8.960	Multiple exodontias	Jaw and Maxillary
5	man	77	Prostate Neo M. Myeloma	Zoledronate	IV	4	28	80	Unknown	Jaw
6	woman	77	Breast Neoplasia	Zoledronate	IV	4	28	56	Multiple exodontias	Maxillary
7	woman	42	Breast Neoplasia	Zoledronate	IV	4	28	72	Unknown	Jaw
8	woman	44	Breast Neoplasia	Zoledronate	IV	4	28	112	Unknown	Maxillary
9	woman	54	Multiple Myeloma	Zoledronate	IV	4	28	108	Multiple exodontias	Jaw
10	woman	53	Breast Neoplasia	Zoledronate	IV	4	28	64	Unknown	Jaw
11	man	47	Prostate Neoplasia	Ibandronate	Oral	50	Daily	19.500		
				Zoledronate	IV	4	28	80	Exodontia	Jaw
12	woman	82	Osteoporosis	Alendronate	Oral	70	7	15.120	Multiple exodontias	Jaw
13	woman	41	Multiple Myeloma	Pamidronate	IV	90	28	2.790	Exodontias	Maxillary
				Zoledronate	IV	4	28	136		
14	woman	76	Osteoporosis	Alendronate	Oral	10	Daily	41.050	Multiple exodontias	Jaw
						70	7	10.920		
15	woman	53	Rectal Neoplasia	Pamidronate	IV	90	28	1.080	Multiple exodontias	Jaw
				Zoledronate	IV	4	28	144	Multiple exodontias	

patients under IV BP administration and 87 months (32-176) for patients under oral BP administration. Patient n° 10 received IV and oral BP treatment for a total of 29 months (16 and 13 months respectively).

We found 10 patients (66,6%) with a history of one or more exodontias. However, no known triggering factors could be identified in the 5 remaining patients.

The average time elapsing between the beginning of BP treatment and the onset of ONJ was 21 months (range 16-28) for patients who had not undergone previous dental treatment. All these patients were under zoledronate treatment, discontinued due to ONJ onset. Only one patient continued with BP therapy with ibandronate for 13 additional months

after being diagnosed with ONJ. The average duration of ONJ in these patients was 21 months (range 11-43).

The most frequent location of the ONJ lesions was the posterior lingual region of the jaw; we found 11 such cases (73,3%), one of them (9%) also with maxillary involvement. We found only 4 cases (26,6%) of maxillary involvement alone. ONJ was unilateral in 14 cases (93,3%) and bilateral in only one case (6,6%).

Bone density alterations were detected in 9 patients (60%) by spine and hip bone densitometry; these included 6 patients diagnosed with osteopenia and 3 diagnosed with osteoporosis. We found pathological vertebral fractures in 40% of patients in spite of being under high BPs doses.

Table II. Personal background. Habits. Concomitant factors.

N°	Sex	Age at menarche (years)	Age at menopause (years)	Number of births	Smoking habits	N°/day	Years	Alcohol consumption	Exercise	Dairy	Ca suppl	Prior treatment for			
												Osteoporosis	Vertebral Fracture	Diabetes	Steroids
1	female	11	53	3	0		0	0	0	1	0	0	0	2	0
2	male			1	1	5	24	0	0	0	0	0	0	2	1
3	female	11	47	2	0			0	0	0	2	1	1	0	1
4	female	13	50	5	0			0	0	0	2	0	0	2	1
5	male				2			3	0	0	1	0	0	0	1
6	female	11	50	2	0			0	0	0	0	0	1	0	0
7	female	9	40	1	1	10	25	0	2	0	0	0	0	0	1
8	female	11	41	2	0			0	0	0	0	0	0	0	1
9	female	12	46	2	0			0	1	0	1	0	1	2	1
10	female	14	44	1	1	30	20	0	1	0	0	0	1	0	1
11	male				1	12	22	2	1	0	0	0	1	0	1
12	female	14	52	4	0			0	0	0	1	0	1	2	0
13	female	12	35	1	1	4	28	0	2	1	2	1	0	0	1
14	female	13	51	0	0			0	0	1	2	1	0	2	0
15	female	12	46	2	1	20	30	0	2	0	0	1	0	0	0

**Values in Table 2:**

Smoking: 0 No 1 yes - 2 Former smoker  
 Alcohol consumption: 0 No 1 Habitually 2 Occasionally 3 Formerly  
 Exercise: 0 No 1 Reduced (<30' per week) 2 Moderate (30'-60' per week)  
 Dairy: 0 < 1200mg Ca/day 1 ≥ 1200mg/day  
 Calcium supplementation: 0 No 1 yes 2 Ca+ vitamin D  
 Previous treatment for osteoporosis: 0 No 1 yes  
 Pathological vertebral fracture: 0 No 1 yes  
 Diabetes 0 No 1 Type-I 2 Type-II  
 Steroids 0 No 1 yes



Table III. Clinical symptoms

Nº	Exposed		Ulcer	Suppuration	Bone loss	Halitosis	Tooth loss	Altered sensation	Skin fistula	Oral-sinus communication	Nausea
	Pain	bone									
1	1	1	1	1	1	1	1	1	0	0	1
2	1	1	0	1	0	1	0	0	0	0	0
3	1	1	1	1	1	1	0	0	0	1	1
4	0	1	0	0	1	0	0	0	0	0	0
5	0	1	0	0	0	0	0	0	0	0	0
6	1	1	1	1	1	1	0	0	0	0	0
7	0	1	0	1	0	1	1	1	1	0	0
8	1	1	0	1	1	1	0	0	0	1	0
9	1	1	0	1	0	1	1	1	0	0	0
10	0	1	1	1	0	1	1	1	1	0	1
11	0	1	1	1	0	1	0	1	1	0	1
12	0	1	0	0	1	0	0	0	0	0	0
13	1	1	0	1	0	1	1	0	0	1	1
14	1	1	0	1	1	1	0	1	0	0	0
15	0	1	0	0	0	0	1	1	0	0	0

Values in table 3: 0 No 1 Yes

Values in table 3: o No 1 Yes

Type II diabetes mellitus had been previously diagnosed to 6 patients (40%). Smoking habit was present in 7 patients (46,6%), who used to smoke a mean of 15 cigarettes/day (range 5-30) for a period of 23 years (range 14-30) on average (Table II).

Regarding the initial ONJ symptom, 9 patients (60%) reported pain, 3 patients (20%) reported inflammation and 3 patients (20%) reported exposed bone into the oral cavity. The most frequently observed symptoms were: ulcerated mucosa with exposed bone (100%) (Figure 1), suppuration (73,3 %), halitosis (73,3%), pain (53,3%), altered sensation in the jaw (46,6%), eating disorders (46,6%) and bone loss (46,6%). Our case series included 3 cases (20%) of submen-

tal fistulae (Figure 2) and 3 cases (20%) of oronasal fistulae and maxillary sinusitis (Table III). The most frequent findings upon examination were: ulcerated mucosa and exposed bone (Figure 3), with suppuration as a consequence of secondary infection (60%).

Biopsy had been performed in 5 cases (33,3%), where the results showed tissue with non-specific signs of chronic and acute inflammation, no evidence of neoplastic signs, and microorganisms whose morphology was suggestive of Actinomyces.

Ortopantomography had been performed in all of the patients and the results mainly showed ONJ-related osteolysis (Figure 4).

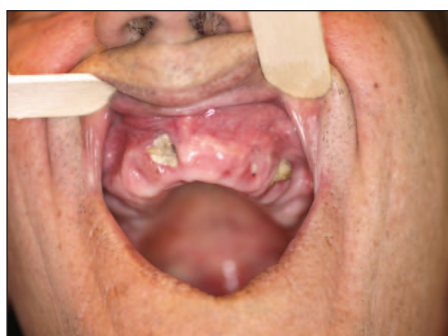

Fig-1

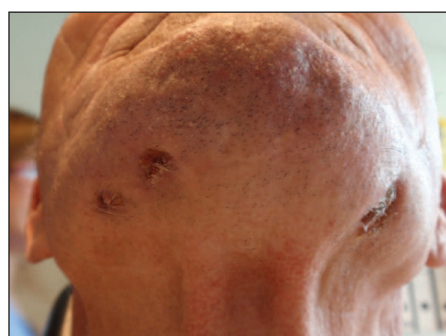

Fig-2

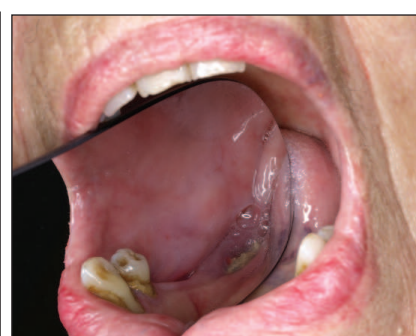

Fig-3

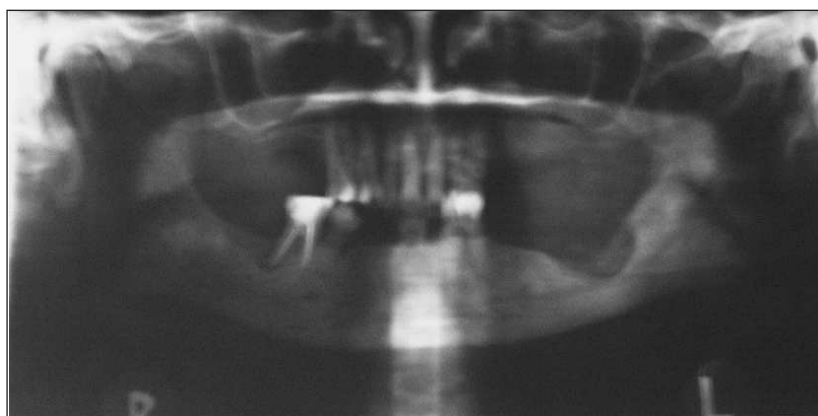


Fig-4

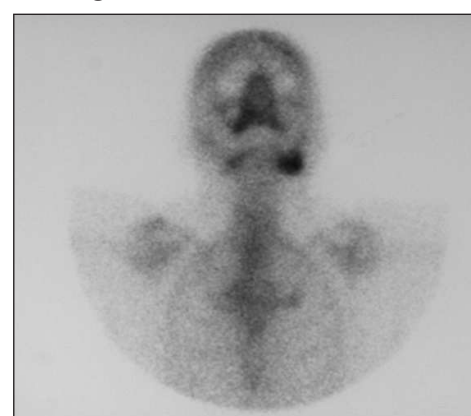

Fig-5

Bone gammagraphy had been performed in 11 patients (73,3%), with rather unspecific results only showing hypercaptation areas (Figure 5).

The therapeutic approach was conservative, with continuous or intermittent cycles of oral systemic antibiotics and mouthwash with chlorhexidine 0.12% for all patients. The most frequently used antibiotic treatment was amoxicillin/clavulanic acid (80%).

Sequestrectomy with mucous flap of the bed was performed in one patient (6,66%); however, this patient again needed sequestrectomy and partial ostectomy of the alveolar process of the mandible two years later. In spite of this, the patient again had exposed bone at the moment of writing this study.

Three patients (20%) with submental fistulae underwent local cures – according to our cure-protocol (20) – with saline solution, ciprofloxacin and hidrogel (Nu-gel®). All of them showed total remission of the fistulae, improvement of their clinical signs, and reduction of feeding difficulties, after 2-3 weeks of treatment.

By the end of this study, 3 patients (20%) showed noticeable clinical improvement and reduction of oral lesions and they were no longer under treatment; 9 patients (60%) still had symptoms, with periods of improvement, depending on the treatment cycles; and 3 patients (20%) had died as a consequence of their underlying diseases.

## DISCUSSION

The first described cases of IV BP-treated patients presenting with non-healing exposed jawbone were reported in 2003 [21,22]. At present, the actual incidence of ONJ is not known. Published studies are retrospective and conducted with restricted sample sizes, most of them consisting in single-case reports. Cumulative estimations of the incidence of ONJ are about 0,8-12% for IV BPs [23,24] and between 1/10.000 and < 1/100.000 exposed persons per year for oral BPs [25]. Evidence shows that the risk of developing ONJ is significantly higher for patients under IV BPs than for those under oral BPs. However the incidence is expected to increase, as more effective diagnosis techniques are developed, better follow up protocols are implemented, and patient exposure to BP treatments becomes more prolonged.

Although other diagnosis criteria are available, we chose those of the AAOMS[19] because they refer both to IV and oral BP treatments.

BPs mechanism of action is still unclear. These drugs are selective inhibitors of osteoclastic actions in the bone remodeling cycle. Due to their antiresorptive action, BPs reduce bone remodeling and, by accelerating secondary mineralization, they induce a fast detectable increase in bone mineral density [12]. Additionally, they seem to have an effect on osteoblasts by reducing apoptosis and stimulating the secretion of inhibitors in the recruitment of osteoclasts [26]. Antiangiogenic effects have also been described, by inhibiting endothelial cells, reducing their proliferation and inducing apoptosis [4].

Since these drugs inhibit bone resorption and are used to prevent and to treat skeletal complications, their relationship with ONJ is difficult to explain. The fact that maxillary bones are subject to higher bone remodeling and in direct contact with the mouth septic environment could partially

account for this outcome [27]. However, establishing a causal relationship requires further research based on prospective randomized double-blind controlled clinical trials [18].

In our 15-patient sample, the age range was 41-82 years with an average of 60, similarly to other published case series [24, 28, 29]. However, we found higher ONJ incidence among women (80%), while other published series reported higher incidence among men [24,2 8, 30].

Although most ONJ cases are associated to IV BPs such as zoledronic acid – used in 80% of our cases – the occurrence of ONJ associated to oral BPs such as alendronate, ibandronate or risendronate, is being increasingly reported in the literature and was also found among our cases (20%) [22].

Similarly to other published case series [27, 29, 31] the most frequently occurring primary diagnosis in our series was breast carcinoma (40%).

Regarding the time of exposure, significant risk of suffering ONJ seems to appear at about 12-14 months of IV BP treatment and to rise after 36 months [18, 26]. These findings lead to recommendations such as the Mayo Clinic guidelines on the use of BPs, where it is advised to discontinue BP therapy after 2 years for patients in a stable phase of their disease or to decrease it every 3 months for patients whose disease remains active [9].

Development of ONJ with oral BPs requires longer treatments and higher doses, because of their poor bioavailability. The risk increases after 3 years of treatment and it would be wise to restrict chronic treatments to a maximum of 5 years [32]. After that time, patients should go on with general measures (balanced diet, moderate exercise, calcium and vitamin D supplementation and quitting smoking). Alternatively, patients may be treated with intermittent administration schedules or with alternative treatments, if the risk of suffering fractures remains high [32].

The most frequent maxillary localization of ONJ lesions was on the jaw (73,3%). The higher involvement of maxillae – as compared with other bones – may be influenced by the fact that they are linked to the teeth through the periodontal ligament, which facilitates the spread of odontogenic and periodontal infections. Other anatomical factors that may promote maxillary involvement are: thinness of the mucosal coating of maxillae – which makes it susceptible to trauma and ulcerative lesions that establish a communication via between mouth and bone – and the terminal vascularization-type of the jaw [33].

Exodontia was the most frequently found related event in our patients' medical records (66,6%). Other published series have reported from 33% [27] to 86% [22] previous exodontias. Further associated risk factors have been reported, such as smoking habits and diabetes (34, 35). Thus, smoker or diabetic patients, as well as patients under concomitant corticoid or anti-neoplastic treatment should be evaluated in more detail. However, cases of spontaneous ONJ onset also occur. In our series, such cases amounted to 33,4%.

In our study, only one of the patients with ONJ associated to oral BPs was under concomitant corticosteroid treatment. This patient presented with ONJ after 32 months of treatment, with onset after a tooth extraction without antibiotic prophylaxis.

Therefore, the management of these patients is rather difficult, since even x-ray examination may yield negative results during the initial stages of the condition [27, 34]. Moreover, standard treatment protocols have not been established. Up to the moment, applied protocols depend on the evolution of the individual patient and the decisions of the medical team in charge.

The primary goals of current ONJ treatments are to control for secondary infections and pain, to prevent extension of existing lesions and development of new necrotic areas, and to raise awareness about the importance of buco-dental hygiene, prosthesis care and regular examinations by a dentistry-stomatology specialist.

Current pharmacological therapy is mainly based on antibiotic therapy and applications of chlorhexidin 0,12% or 0,2%. We consider that local cures (20) should be added to the treatment of ONJ patients with skin fistulae, at least until a definitive treatment is found.

Surgical debridement is not completely effective to remove necrotic bone. Surgical treatments include sequestrectomy, maxillectomy and total or partial mandibulectomy, where obtaining surgical margins with vascularized bone tissue is very difficult [29, 35, 36].

Hyperbaric oxygen therapy has proven ineffective in limiting the progression of this condition [18, 24, 27, 30, 34, 35, 36] although pain relief after hyperbaric oxygen combined with antibiotics has been occasionally reported [37].

BPs are not metabolized in the body; they persist the bones for months or years after administration is discontinued. Therefore, discontinuing BPs does not seem to accelerate recovery from ONJ [1, 18, 34]. However, three patients under oral BPs in our series, showed improvement of their clinical signs 5-6 months after treatment discontinuation.

Due to the complexity of the treatment and the uncertainty of the results, prevention and patient information should be the primary objectives.

### CONCLUSIONS

The osteonecrosis of the jaw is a condition that affects mainly to patients in advanced ages – 60 years on average – and is more prevalent in women.

It is important to individualize each patient by evaluating the administered BP, route of administration – IV or oral – duration of treatment, administered doses, primary disease and possible concomitant diseases or treatments. We observed a direct relationship with the time of exposition to BP and the accumulated dose.

Zoledronate seems to be the BP most frequently associated to ONJ, probably because it is the most potent and most frequently used one for IV administration.

Jaw is the most frequent location for this condition (73,3%). From all known triggering factors, previous exodontia appears to be the most strongly related one.

ONJ diagnosis is mainly based on clinical findings without the need for complementary tests or biopsy.

The treatment depends on the characteristics and progression of every individual case.

Prevention is the best approach to this condition. Providing correct information to patients and coordinating medical and dental assistance seem to be essential for preventing it.

---

### Apstrakt

**Uvod:** Osteonekroza vilica (ONV) je novootkrivena komplikacija bifosfonatne terapije (BP), prvi put opisana 2003, koja nije zapažena u ranijim kliničkim ispitivanjima. Cilj ovog istraživanja bila je evaluacija kliničkih karakteristika kod 15 pacijenata sa osteonekrozom vilica povezanom sa terapijom bifosfonatima da bi se postigla bolja strategija lečenja.

**Metod:** U ispitivanje je bilo uključeno 15 pacijenata sa osteonekrozom vilica izabраниh prema kriterijumima Američke asocijacije oralnih i maksilofacijalnih hirurga. U studiji su analizirani: tip bifosfonatne terapije, put inošenja bifosfata, komorbiditet, kliničko ispoljavanje i rezultati dijagnostičkih testova.

**Rezultati:** Ispitivano je 12 žena i 3 muškarca čija je prosečna starost bila 60 godina. Od njih 15, troje je bilo sa oralnom terapijom bifosfatima, a 12 sa intravenskom terapijom. Prosečno trajanje lečenja iznosilo je 29,8 meseci sa intravenskom i 87 meseci sa oralnom bifosfonatnom terapijom. Većina analiziranih slučajeva bila je udružena sa upotrebom zoledronata (80%). Karcinom dojke bio je najčešća prateća bolest (40%). Vilica je bila najčešća lokalizacija osteonekroze (73,3%), a egzodontija zuba najčešći trigerirajući faktor (66,6%).

**Zaključak:** Osteonekroza vilica je stanje koje pogada uglavnom starije pacijente. Bitno je da se svaki slučaj individualno procenjuje u zavisnosti od tipa bifosfonatne terapije, puta unošenja (oralno ili intravenski), dužine trajanja lečenja, primljene doze leka, primarne bolesti i mogućih udruženih bolesti ili terapija. Osteonekroza vilica se uglavnom bazira na kliničkom nalazu. Studija je pokazala se da je prevencija najbolja strategija za ovo stanje.



## REFERENCES

1. Cuevas V, Martínez I, Fernández M, Zamora M, Álamo O. Osteonecrosis del maxilar en paciente con mieloma múltiple tratado con bisfosfonatos *Rev Electron Biomed/ Electron J Biomed* 2006; 3: 14-28.
2. Kanterewicz Binstock E. Bisfosfonatos. *Rev Esp. Reumatol* 2004; 31:9-12.
3. Jiménez-Soriano Y, Bagan JV. Bisfosfonatos, as a new cause of drug-induced jaw osteonecrosis: an update. *Med Oral Patol Oral Cir Bucal* 2005; 10: E88-91.
4. Wood J, Bonjean K, Ruetz S, Bellahcene A, Devy L, Foidart JM, et al. Novel antiangiogenic effects of the bisphosphonates compound zoledronic acid. *J Pharmacol Exp Ther* 2002; 302: 1055-61.
5. Major P, Lortholary A, Hon J, Abdi E, Mills G, Menssen HD, et al. Zoledronic acid is superior to pamidronate in the treatment of hypercalcemia of malignancy: a pooled analysis of two randomized, controlled, clinical trials. *J Clin Oncology* 2001; 19: 558-67.
6. Hillner BE, Ingle JN, Chelbowski RT, Gralow J, Yee GC, Janjan NA, et al. American Society of Clinical Oncology 2003 update on the role of bisphosphonates and bone health issues in women with breast cancer. *J Clin Oncol* 2003; 21: 4042-57. Epub 2003 Sep 8. Erratum in: *J Clin Oncol* 2004; 22:1351.
7. Saad F, Gleason DM, Murray R, Tchekmedyian S, Venner P, Lacombe L, et al. Long-term efficacy of zoledronic acid for the prevention of skeletal complications in patients with metastatic hormone-refractory prostate cancer. *J Natl Cancer Inst* 2004; 96: 879-82.
8. Berenson JR, Hillner BE, Kyle RA, Anderson K, Lipton A, Yee GC, et al. American Society of Clinical Oncology clinical practice guidelines: the role of bisphosphonates in multiple myeloma. *J Clin Oncol* 2002; 20: 3719-36.
9. Lacy MQ, Dispenzieri A, Gertz MA, Greip R, Gollbach KL, Hayman SR, et al. Mayo clinic consensus statement for the use of bisphosphonates in multiple myeloma. *Mayo Clin Proc* 2006; 81: 1047-53. Review.
10. Farrugia MC, Summerlin D-J, Krowiak E, Huntley T, Freeman S, Borrowdale R et al. Osteonecrosis of the mandible or maxilla associated with the use of new generation bisphosphonates. *Laryngoscope* 2006; 116: 115-20.
11. Bertó A, Miñana M, Miñana R. ONM (Osteonecrosis de los maxilares relacionada con bisfosfonatos). Guía para el tratamiento y prevención en endodoncia. *Gaceta Dental* 2007; 179: 106-24.
12. Reid IR, Brown JP, Burckhardt P, Horowitz Z, Richardson P, Trechsel U, et al. Intravenous zoledronic acid in postmenopausal women with low bone mineral density. *N Engl J Med* 2002; 346: 653-61.
13. Black DM, Delmas PD, Eastell R, Reid IR, Boonen S, Cauley JA, et al. Once-yearly zoledronic acid for treatment of postmenopausal osteoporosis. *N Engl J Med* 2007 ; 356: 1809-22.
14. Delmas PD. The use of bisphosphonates in the treatment of osteoporosis. *Curr Opin Rheumatol* 2005; 17: 462-6. Review.
15. Liberman UA, Weiss SR, Bröll J, Minne HW, Quan H, Bell NH, et al. Effect of oral alendronate on bone mineral density and the incidence of fractures in postmenopausal osteoporosis. The alendronate phase III osteoporosis treatment study group. *N Engl J Med* 1995; 333: 1437-43.
16. Rudge S, Haiwood S, Horne A, Lucas J, Wu F, Cundy T. Effects of once-weekly oral alendronate on bone in children on glucocorticoid treatment. *Rheumatology* 2005; 44: 813-8.
17. Silverman SL, Landesberg R. Osteonecrosis of the jaw and the role of bisphosphonates: a critical review. *Am J Med* 2009; 122: S33-45.
18. Heras-Rincón I, Zubillaga-Rodríguez I, Castrillo-Tambay M, Montalvo-Moreno JJ. Osteonecrosis of the jaws and bisphosphonates. Report of fifteen cases. Therapeutic recommendations. *Med Oral Patol Oral Cir Bucal* 2007; 12: E 267-71.
19. American Association of Oral and Maxillofacial Surgeons. 2006 position paper on bisphosphonate-related osteonecrosis of the jaws. Available at: [http://www.aaoms.org/docs/position\\_papers/osteonecrosis.pdf](http://www.aaoms.org/docs/position_papers/osteonecrosis.pdf). Accessed feb 15, 2010.
20. Pérez SB, Barrero MV, Hernández MS, Knezevic M, Navarro JM, Millares JR. Osteonecrosis maxilar asociada al uso de bisfosfonatos. Una propuesta para el tratamiento conservador. *Med Oral Patol Oral Cir Bucal*. 2009 *Ener*; 14 (1): 32-5.
21. Marx RE. Pamidronate (Aredia) and zoledronate (Zometa) induced avascular necrosis of the jaws: A growing epidemic. *J Oral Maxillofac Surg* 2003; 61: 1115-7.
22. Ruggiero SL, Mehrotra B, Rosenberg TJ, Engroff SL. Osteonecrosis of the jaws associated with the use of bisphosphonates. A review of 63 cases. *J Oral Maxillofac Surg* 2004; 62: 527-34.
23. Durie B, Katz M, Crowley J. Osteonecrosis of the jaw and bisphosphonates. *N Engl J Med* 2005; 353: 99-102.
24. Bamias A, Kastiris E, Bamia Ch, Mouloupoulos L, Melakopoulos I, Bozas G, et al. Osteonecrosis of the jaw in cancer after treatment with bisphosphonates: incidence and risk factors. *J Clin Oncol* 2005; 23: 8580-7.
25. Khosla S, Burr D, Cauley J, Dempster DW, Ebeling PR, Felsenberg D, et al. American Society for Bone and Mineral Research. Bisphosphonate-associated osteonecrosis of the jaw: report of a task force of the American Society for Bone and Mineral Research. *J Bone Miner Res*. 2007 Oct; 22(10):1479-91.
26. Ponte Fernández N, Estefanía Fresco R, Aguirre Urizar JM. Bisphosphonates and oral pathology I. General and preventive aspects. *Med Oral Patol Oral Cir Bucal* 2006; 11: E396-400.
27. Migliorati CA, Schubert MM, Peterson DE, Seneda LM. Bisphosphonate-associated osteonecrosis of mandibular and maxillary bone: an emerging oral complication of supportive cancer therapy. *Cancer* 2005; 104: 83-93.
28. Badros A, Weikel D, Salama A, Golubeva O, Schneider A, Rapoport A, et al. Osteonecrosis of the jaw in multiple myeloma patients: clinical features and risk factors. *J Clin Oncol* 2006; 24: 945-52.
29. Bagán JV, Jiménez Y, Murillo J, Hernández S, Poveda R, Sanchis JM, et al. Jaw osteonecrosis associated with bisphosphonates: multiple exposed areas and its relationship to teeth extractions. Study of 20 cases. *Oral Oncology* 2006; 42: 327-9.
30. Melo MD, Obeid G. Osteonecrosis of the jaws in patients with a history of receiving bisphosphonate therapy: strategies for prevention and early recognition. *J Am Dent Assoc* 2005; 136: 1675-81.
31. Pires FR, Miranda A, Cardoso ES, Cardoso AS, Fregnani ER, Pereira CM, et al. Oral avascular bone necrosis associated with chemotherapy and bisphosphonate therapy. *Oral Dis* 2005; 11:365-9.
32. Sánchez A. Bisfosfonatos: ¿por cuánto tiempo?. *Actualiz Osteología* 2006; 2: 86-8.
33. Escobar EA, López J, Marques MS, Chimenos E. Osteonecrosis de los maxilares asociada a bisfosfonatos: revisión sistemática. *Av. Odontostomatol* 2007; 23: 91-101.
34. Woo SB, Hellstein JW, Kalmar JR. Systematic review: bisphosphonates and osteonecrosis of the jaws. *Ann Intern Med* 2006; 144: 753-61. Erratum in: *Ann Intern Med*. 2006; 145: 235.
35. Marx RE, Sawatari Y, Fortin M, Broumand V. Bisphosphonate-induced exposed bone (osteonecrosis/osteopetrosis) of the jaws: risk factors, recognition, prevention and treatment. *J Oral Maxillofac Surg* 2005; 63: 1567-75.
36. Ruggiero SL, Fantasia J, Carlson E. Bisphosphonate-related osteonecrosis of the jaw: background and guidelines for diagnosis, staging and management. *Oral Surg Oral Med Oral Pathol Oral Radiol Endod* 2006; 102: 433-41. Epub 2006 Jul 31.
37. Shimura K, Shimazaki Ch, Taniguchi K, Akamatsu S, Okamoto M, Uchida R, et al. Hyperbaric oxygen in addition to antibiotic therapy is effective for bisphosphonate-induced osteonecrosis of the jaw in a patient with multiple myeloma. *Int J Hematol* 2006; 84: 343-5.